

*The Place of Cryopreserved Amniotic Membrane in Treatment Protocols for Cornea-involved Ocular Surface Disease and Before Refractive Cataract Surgery*

# Redefining the Standard of Care

## A Consensus Guideline

*Marguerite McDonald, MD*

*Neel Desai, MD*

*Mark Milner, MD*

*Clifford Salinger, MD*

*John Sheppard, MD, MMSc*

*Developed from a roundtable discussion conducted by Bio-Tissue*

Bio-Tissue distributes this reprint for educational purposes only. The article contains information about certain Bio-Tissue amniotic membrane products that are not included in the products' Food and Drug Administration-cleared labeling.

Specifically, FDA has not reviewed any Bio-Tissue data to suggest that any of its products provide any anti-microbial effects, properties, or action or any nerve corneal regenerative therapeutic or healing benefits. The Bio-Tissue products do not have marketing authorization for these uses, and the company does not promote its products for such uses.

Drs. McDonald, Desai, Milner, Salinger and Sheppard, participants in the roundtable discussion and authors of the Consensus Guideline, are paid consultants of Bio-Tissue. Please reference the Instructions for Use for those Bio-Tissue products that are referenced in the article online at <https://www.biotissue.com/packaging-storage/>.

## INTRODUCTION

This consensus guideline has been developed in order to reexamine the role of cryopreserved amniotic membrane (CAM) in the management of cornea-involved ocular surface diseases and the preparation of the ocular surface for refractive cataract surgery, all of which present continued unmet needs. As the authors of this guideline, we use the term “cornea-involved ocular surface diseases” as distinct from the common term “ocular surface diseases.” The latter is more comprehensive, encompassing conditions such as meibomian gland dysfunction (MGD) and mucin/goblet cell deficiency. Cornea-involved ocular surface diseases include persistent epithelial defect (PED), corneal ulcer/infectious keratitis, recurrent corneal erosion (RCE), severe dry eye disease (DED), epithelial basement membrane dystrophy (EBMD), and neurotrophic keratitis (NK).

In addition, we use the term “cornea-involved ocular surface disease” for both defect-based and inflammation-induced diseases involving the cornea. Defect-based, cornea-involved ocular surface diseases are those in which a defect plays a central role, although these diseases may also involve inflammation. Inflammation-induced, cornea-involved ocular surface diseases are those in which inflammation plays a fundamental role, but a defect is not necessarily created.

### *Existing Standards of Care*

Existing standards of care are outdated for a number of these diseases; many rely too heavily on palliative treatments and fail to recommend disease-modifying therapies early enough in the treatment algorithm<sup>1-3</sup> For example, while we strongly agree that superficial keratectomy followed by application of CAM should be the standard of care for treatment of RCE, the American Academy of Ophthalmology’s most recent recommendations on treatment of RCE contain no mention of CAM.<sup>3</sup> The standards of care for many cornea-involved ocular surface diseases, including RCE, routinely recommend bandage contact lenses (BCL) to passively aid in re-epithelialization, but BCL pose inherent risks including infectious keratitis, DED, inflammation, and corneal hypoxia and edema.<sup>4</sup>

### *Amniotic Membrane*

Our collective experience with amniotic membrane (AM) for treating cornea-involved ocular surface diseases and presurgical optimization of the ocular surface has motivated a revision of current treatment protocols to include more proactive use of AM at earlier stages.

The innermost membrane of the amniotic sac, AM is a vital tool for the treatment of a variety of ocular surface conditions. AM acts as a bandage that protects damaged tissue and, as a disease-modifying therapy, promotes regenerative wound-healing.<sup>5-7</sup>

Two types of AM are used for ophthalmic purposes: cryopreserved and dehydrated. CAM is kept frozen until shortly before use. Dehydrated AM is stored at room temperature and rehydrated just before use.

### *Cryopreserved Amniotic Membrane*

The cryopreservation process allows CAM to retain heavy chain peptide (HC) covalently conjugated with high molecular weight hyaluronic acid (HA), which is noncovalently complexed with pentraxin-3 (PTX3)—HC-HA/PTX3, referred to throughout this consensus guideline as cryopreserved amniotic membrane complex (CAM-C)—a biologic matrix that is responsible for CAM’s antiinflammatory and regenerative healing properties. HA and PTX3 are involved in tissue repair and remodeling; and HC components of immunoglobulin form complexes with HA. Each component of CAM-C is found broadly in the human body—but they only exist together, as a complex, in the fetus and amniotic membrane.<sup>5,8</sup> It is CAM-C that provides the fetal regenerative healing, characterized by a limited inflammatory and fibrotic response, which is maintained in cryopreservation but lost in dehydration (Figures 1 and 2).<sup>9</sup>

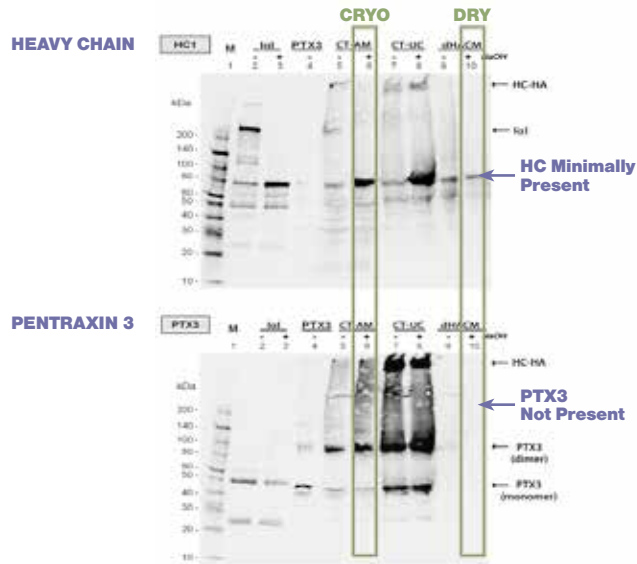
CAM-C products come in two forms: 1) self-retained and sutureless (PROKERA®, PROKERA® Slim, PROKERA® Plus, and PROKERA® Clear; Bio-Tissue, Miami, FL); and 2) transplantation grafts that can be sutured or glued (AmnioGraft®; Bio-Tissue, Miami, FL). PROKERA®, PROKERA® Slim, PROKERA® Plus, and PROKERA® Clear have been cleared by the FDA

as class II medical devices. All CAM-C products—that is, all PROKERA® products and AmnioGraft®—have antiinflammatory, antiscarring, and antiangiogenesis properties as designated by the FDA.

Dehydrated AM products have no formal medical designation from the FDA, and their only indication is for wound coverage.<sup>10</sup>

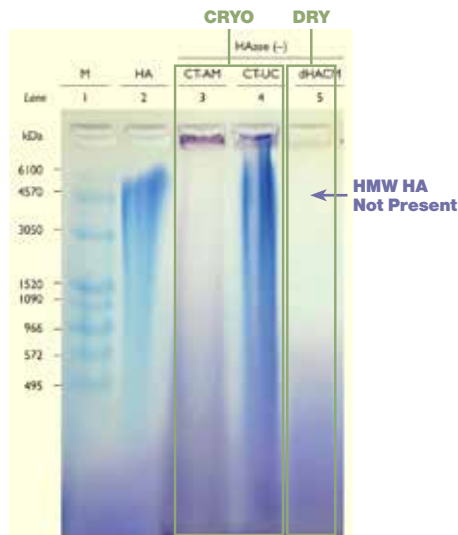
In PROKERA products, the cryopreserved amniotic membrane is bounded by a clear polymer ring. These products require no assembly and are inserted into the eye in a manner similar to contact lens placement.<sup>10</sup> AmnioGraft® is a transplantation graft of cryopreserved amniotic membrane that does not contain a polymer ring. It is applied surgically to treat corneal ulcers, pterygium, mechanical dry eye (also known as conjunctivochalasis), excision of tumors, chemical burns, and Stevens-Johnson syndrome.<sup>11</sup>

CAM-C has a number of effects that promote regenerative healing in all cornea-involved ocular surface diseases. Specifically, CAM-C suppresses inflammation by facilitating neutrophil apoptosis, polarizing M1 to M2 macrophages, and suppressing Th1 and Th17 lymphocyte activation;



**Figure 1.** Western blots showing the degree to which CAM retains HC and PTX3, while dehydrated amniotic membrane is depleted of these components. Adapted from figures 5 and 6 of Cooke M, Tan EK, Mandrycky C, He H, O’Connell J, Tseng SC. Comparison of cryopreserved amniotic membrane and umbilical cord tissue with dehydrated amniotic membrane/chorion tissue. *J Wound Care.* 2014;23(10):465-74, 476. CT-AM: cryopreserved amniotic membrane, CT-UC: cryopreserved umbilical cord, dHACM: dehydrated human amnion/chorion membrane, PTX3: pentraxin 3, HC-HA: heavy chain hyaluronic acid, HC1: heavy chain 1.

**HMW HYALURONIC ACID**



**Figure 2.** Assay showing the degree to which CAM retains HA while dehydrated amniotic membrane is depleted of it. HMW: high molecular weight. Adapted from figure 4 of Cooke M, Tan EK, Mandrycky C, He H, O’Connell J, Tseng SC. Comparison of cryopreserved amniotic membrane and umbilical cord tissue with dehydrated amniotic membrane/chorion tissue. *J Wound Care.* 2014;23(10):465-74, 476. HA: hyaluronic acid, HMW: high molecular weight, CT-AM: cryopreserved amniotic membrane, CT-UC: cryopreserved umbilical cord, dHACM: dehydrated human amnion/chorion membrane.

inhibits scarring by preventing myofibroblast differentiation and reprogramming into progenitor cells; and promotes regenerative healing by supporting and augmenting mesenchymal stem cell function and maintaining stem cell quiescence.<sup>5</sup>

#### *Place of CAM-C in Revised Treatment Protocols*

In this consensus guideline, we discuss the optimal place of CAM-C in treatment protocols for defect-based ocular surface diseases, including PED, corneal ulcer/infectious keratitis, and RCE; for inflammation-induced ocular surface diseases, including EBMD, severe DED, and NK; and for preparing the ocular surface prior to refractive cataract surgery.

## TREATMENT PROTOCOLS FOR DEFECT-BASED, CORNEA-INVOLVED OCULAR SURFACE DISEASE

### *Persistent Epithelial Defect*

#### **BACKGROUND**

PED is defined as an epithelial defect that shows no or minimal decrease in size, or an increase in size, over the course of 48 to 72 hours.<sup>12</sup> In some patients, it is possible to see the gray rolled edges of the defect and the exposed Bowman's layer loaded with denatured material.

PED occurs in about 100,000 patients in the United States annually and is common in the cornea specialist's practice.<sup>12</sup> PED is associated with exposure keratopathy, limbal stem cell deficiency, herpes simplex, herpes zoster, diabetic keratopathy, neurotropic keratopathy, corneal transplantation, diabetic vitrectomy, severe DED, corneal burns, and uncontrolled inflammation.<sup>12</sup>

#### *Limitations of Conventional Standard of Care*

The conventional standard of care for PED includes lubricants, preservative-free agents, BCL, temporary or permanent suture or pillar tarsorrhaphy, and full thickness or lamellar corneal transplants.<sup>1</sup>

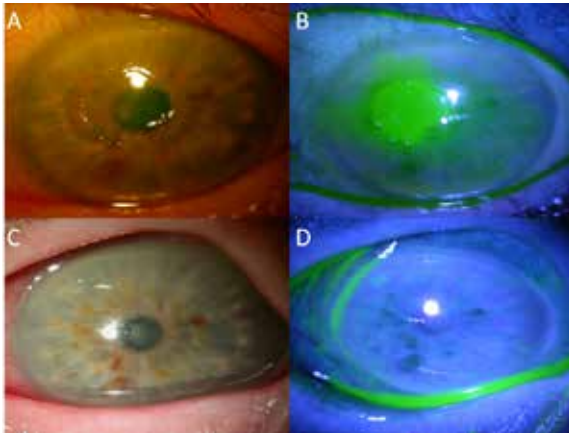
The conventional standard of care is suboptimal. Only about 60% of PED patients will be healed with in 4 weeks when treated with conventional therapy.<sup>13</sup> Lubricants are insufficient, soft BCL are hypoxic to the epithelium, and scleral BCL necessitate meticulous fitting and added expense.

BCL increase risk in the presence of epitheliopathy, delayed epithelialization and Bowman's membrane adhesions, or neurotrophic disease. For example, overnight wear of soft BCL polymers increases the risk of infectious keratitis, particularly in the presence of an epithelial defect. Finally, corneal scarring as a result of PED may necessitate a corneal transplant, which involves a risk of rejection, melt, and poor healing.

#### **HOW CAM-C TREATS PED**

CAM-C is an effective therapy for PED in a variety of ocular surface diseases and corneal surgeries.<sup>14</sup> CAM-C is able to treat PED because it has antiinflammatory effects;<sup>15,16</sup> produces rapid reepithelialization of the cornea with minimal or no scarring;<sup>17-20</sup> reduces trauma from the blink reflex;<sup>18</sup> and regenerates corneal nerves.<sup>15,16</sup> In contrast to BCLs, CAM-C prevents infection because of its antimicrobial effects, which are inherent and well-preserved in CAM.<sup>17,21-24</sup>

In addition to reducing the clinical signs of PED (Figure 3), CAM-C reduces the symptoms of the condition.<sup>15-20</sup> Some patients may experience a sensation of "fullness" in the eye due to the support ring; but in the majority of patients, the protective, antiinflammatory effect over the defect reduces foreign body sensation.



**Figure 3.** These slit-lamp photos, taken before (A and B) and after (C and D) treatment with CAM-C (PROKERA®; Bio-Tissue, Miami, FL) as well as with and without fluorescein dye, show how CAM-C heals PED. We recommend treatment with CAM-C for 5 to 9 days. Courtesy of Bio-Tissue.

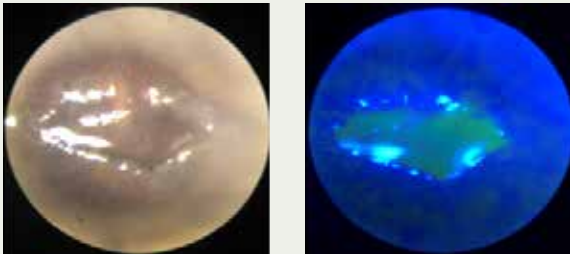
### Case Presentation: CAM-C for Treatment of PED (Courtesy of Dr. McDonald)

78-year-old white female.

#### HISTORY

- Herpes simplex virus
- DED
- Entropion

#### EXAMINATION



**Figure 4.** Slit lamp photography revealing large, central, 2 mm high x 5 mm wide persistent epithelial defect with scrolled epithelium bordering the lesion. Fluorescein staining reveals punctate keratopathy due to DED and intact Bowman's layer.

#### DIAGNOSIS

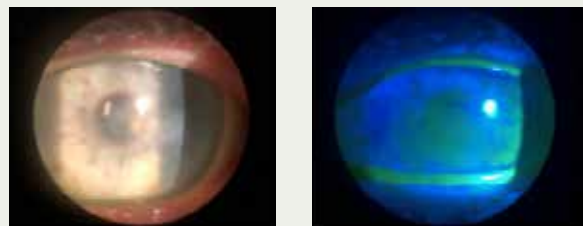
- PED with DED
- Viral NK

#### TREATMENT

- 5/22/19: Acyclovir, punctal plugs, preservative-free artificial tears (AT), oral doxycycline
- 5/29/19: Therapeutic BCL
- 6/12/19: CAM-C (PROKERA®; Bio-Tissue, Miami, FL)
- 10/2/19: 1-month topical difluprednate ophthalmic emulsion 0.05% (Durezol; Novartis, Basel, Switzerland) BID

#### FOLLOW-UP

- 3 months after application of CAM-C



**Figure 5.** The epithelial defect has completely healed, and the punctate keratopathy has resolved, but a mild, temporal paracentral subepithelial haze persists.

### *Optimal Place of CAM-C in Revised Treatment Protocol of PED*

Any patient with PED is a good candidate for CAM-C. If the PED is not responding to passive wound-coverage therapies such as BCL and/or the patient has additional risk factors for infection or slow, delayed healing, then CAM-C should be considered.

However, the ideal time to use CAM-C for PED is not after weeks of passive, traditional therapies but first line, at the point of initial injury. Once the inflammatory cascade is initiated, macrophages are activated, and fibroblasts start laying down scar tissue.<sup>5,35</sup> Earlier intervention with CAM-C may prevent potentially irreversible damage from NK.<sup>36</sup> As noted above, CAM-C has anti-scarring, antiinflammatory, and anti-angiogenic properties

and can help corneal nerve regeneration.<sup>15-20</sup>

### *CAM-C for Treatment of Other Epithelial Defects*

CAM-C should also be considered early in the treatment algorithm for epithelial defects that are at high risk for delayed healing and scarring. For example, CAM-C may be an optimal early intervention for epithelial defects in patients who have a propensity for poor healing due to concurrent diabetes, a history of herpetic keratitis, and/or neurotrophic cornea; in patients with exposure keratopathy and/or a poor blink reflex due to age, neurodegenerative disease, or other factors; or in patients who have sustained trauma to the cornea and are at risk of developing persistent epitheliopathies.

## Corneal Ulcer/Infectious Keratitis

### *Background*

Infectious corneal ulcer, which may be a manifestation of infectious keratitis, has many possible etiologies: viral, bacterial, protozoan, fungal, or secondary to other rare organisms.<sup>37</sup>

Infectious corneal ulcers are a common cause of visual impairment and corneal blindness worldwide, especially in the developing world, where they are often associated with corneal trauma. In the US, corneal ulcers are most often associated with contact lens wear.<sup>38</sup>

### *Limitations of Conventional Standard of Care*

The conventional standard of care for infectious keratitis dictates treatment of the infection with targeted antimicrobials, topical steroids, and other measures to heal the cornea.<sup>2,38,39</sup> The conventional therapies often leave a choice between inflammation control or enhanced healing.<sup>38</sup>

### *How CAM-C Treats Corneal Ulcer/Infectious Keratitis*

CAM-C has the ability to manage healing via the presence of collagen and growth factors, along with counteracting the potentially cytotoxic effects of topical antibiotics. Walter and Tyler, for example, reported two cases of worsening of infectious corneal ulcer after moxifloxacin treatment in humans.<sup>40</sup> Conversely, in a study of three patients with bacterial

keratitis, CAM-C use was associated with enhanced epithelialization and reduced pain, visual haze, and inflammation.<sup>39</sup>

CAM-C provides antimicrobial effects over and above those of the first-line antibiotics; improves epithelial healing; prevents perforation, scarring, and irregular astigmatism; and regenerates corneal nerves.<sup>5,7,15,21-34,41</sup>

The two major visual sequelae of infectious keratitis, especially involving the visual axis, are scarring and ectasia; and both can be prevented, reduced, or remediated with CAM-C.<sup>7,41-43</sup> The Steroids for Corneal Ulcer Trial (SCUT) showed that some patients with bacterial keratitis involving the visual axis may benefit from topical steroid intervention in addition to topical antibiotics, but many patients fared no better with adjunctive steroids than placebo—and some, such as patients with ulcers caused by *Nocardia* species, fared worse with steroids.<sup>44</sup> Other studies have shown that steroids are ineffective for corneal ulcer/infectious keratitis. CAM-C, on the other hand, provides effective antiinflammatory therapy with a better safety profile than topical steroids, which can delay healing, reactivate a viral infection, cause cataract formation, and elevate intraocular pressure (IOP).<sup>44,45</sup>

## Case Presentation: CAM-C for Treatment of Corneal Ulcer/Infectious Keratitis (Courtesy of Dr. Sheppard)

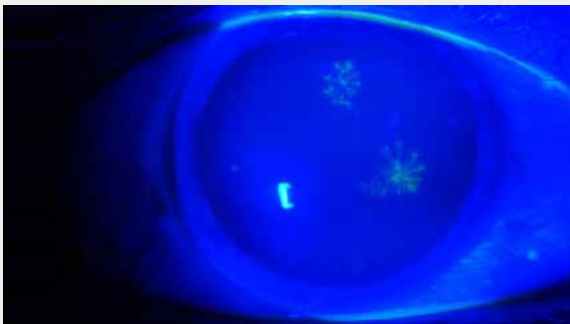
48-year-old Hispanic male.

### HISTORY

- Recurrent herpes simplex virus responds to topical ganciclovir
- Intolerant of oral acyclovir
- Previous therapy with trifluridine induced NK and DED

### EXAMINATION

- Irregular mires and topography



**Figure 6.** Recurrent diffuse dendritic NK with irregular astigmatism.

### DIAGNOSIS:

- Corneal ulcer/infectious keratitis of viral origin/irregular astigmatism

### TREATMENT

- Topical ganciclovir induction therapy
- Topical cyclosporine maintenance therapy
- CAM-C (PROKERA<sup>®</sup>; Bio-Tissue, Miami, FL)

### FOLLOW-UP

- DED with superficial punctate keratitis improved after cyclosporine therapy
- Superior visual and topographic results with 7 days of treatment with CAM-C. With a reduction in corneal topographic irregularity, the patient's best-uncorrected visual acuity improved while avoiding previously ineffective or irritating medications. The regenerative and antiinflammatory effects of CAM-C produced desirable surface healing while avoiding topical steroid toxicity. Thus, CAM-C as a steroid-sparing antiinflammatory intervention becomes particularly fruitful in herpetic keratitis where topical steroids may enhance viral replication.

### Optimal Place of CAM-C in Revised Treatment Protocol of Corneal Ulcer/Infectious Keratitis

We use CAM-C as soon as possible after the etiology of the corneal ulcer/infectious keratitis is determined. Using CAM-C early in the clinical course of a corneal ulcer provides a powerful antiinflammatory effect without the concern of delayed healing that accompanies treatment with a topical steroid.

In cases of a negative initial Gram stain or an undetermined pathogen, we wait for a positive culture and/or a response to initial antimicrobial therapy and then immediately initiate therapy with CAM-C, before a scar has formed. This includes patients with Gram-negative bacterial keratitis,

which indicate a higher risk of keratolytic disease leading to corneal stromal necrosis and perforation from destructive collagenase, protease<sup>46</sup>, and metalloprotease enzymes.<sup>47</sup> For example, *Klebsiella*, *Serratia*, and *Pseudomonas* ulcer patients are much more likely to develop a soupy, necrotizing stromal keratitis, leading to stromal scarring, keratographic abnormalities, and decreased vision. Many of these patients are less-than-ideal candidates for a corneal transplant and at risk of permanent haze and topographic abnormalities that could have been mitigated by appropriate antiinflammatory therapy such as CAM-C.

In patients with suspected viral infections, we use CAM-C as soon as possible after determining

whether the infection is poly-microbial: viral NK or super-infected with bacteria. Determining the initial source(s) of the infection, which may require both bacterial and viral cultures or smears. Corneal sensation testing of the unanesthetized cornea revealing significant hypoesthesia further indicates a viral etiology. Clinical observation of injection, ciliary flush, anterior chamber cells, corneal infiltrates, stromal melting, keratic precipitates, or stromal inflammatory cells all clearly indicate the presence of an inflammatory component and therefore require antiinflammatory intervention.

Both bacterial and viral infectious keratitis are appropriately targeted with CAM-C during an active infection because of its antimicrobial properties and because the infection can still be monitored with fluorescein under the CAM-C.<sup>21-34</sup> Furthermore, IOP measurements can even be taken using an applanation tonometer with the membrane in place.

An in vitro study of CAM soaked in an antibiotic demonstrated that the antibiotic was detectable in under a minute and continued to be released steadily at a minimum inhibitory concentration for most bacteria sensitive to the antibiotic for up to 7 hours.<sup>48</sup> The CAM acted similarly to a slow- or sustained-release drug depot or drug-eluting stent. This in vitro drug permeability study suggests that CAM-C deployed concomitantly topical antimicrobials may help to even out peaks and troughs of antibiotic levels in tears or corneal or ocular surface tissues.<sup>21-34,48</sup>

In cases where it is challenging to monitor the ulcer after applying the CAM, we recommend removing

the membrane with sterile jewelers or toothed forceps, placing it in a sterile container, conducting the exam, rinsing off the membrane with sterile saline, and re-inserting it.

In patients with suspected protozoan or fungal keratitis, we consider use of CAM-C only after the diagnosis is confirmed by culture, smear, or confocal microscopy, or if there is response to specific topical therapy. Confocal microscopy can be very helpful in diagnosing protozoan or fungal keratitis. More data on the use of CAM-C for protozoan or fungal keratitis is needed. That being said, CAM-C may be useful after aggressive debridement, which is often considered in cases of fungal keratitis if there is an epithelial component (in order to enhance the absorption of anti-fungal medications)—and which is the initial treatment of choice for presumed *Acanthamoeba* keratitis.<sup>49</sup>

Some patients with a very active infection—regardless of etiology—may require replacement with a new CAM. If the membrane begins to dissolve or stops looking translucent and appears more opaque, it may have released all of its biologics, requiring replacement, not reinsertion.

For patients with a typical bacterial (particularly pseudomonal) corneal ulcer, we follow up within 48 to 72 hours because the ulcers are quick to melt the stroma, and the CAM may dissolve quickly. We replace the membrane if it is opaque, has a “Swiss cheese” appearance, or if the ring is empty. For patients with viral keratitis, we follow up within 1 week and replace the CAM using similar criteria.

## Recurrent Corneal Erosion

### Background

RCE typically occurs in patients who have a history of ocular trauma, such as abrading injuries from fingernails or paper cuts, epithelial injury from excessive water exposure or radiant heat dessication, or following cataract or refractive surgery.<sup>50</sup> In addition, approximately 19% to 29% of RCE cases are associated with EBMD.<sup>50</sup> The incidence of RCE is increased in patients with DED, blepharitis, diabetes mellitus, and/or ocular rosacea.<sup>50</sup>

### Limitations of Conventional Standard of Care

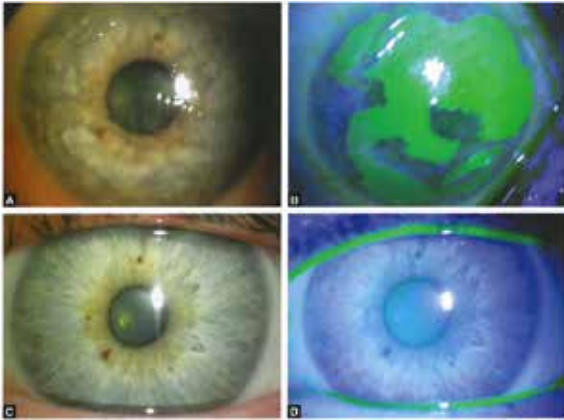
RCE is typically treated with a course of hypertonic saline solution or ointment, antibiotic and lubricating drops, BCL, cycloplegics, and systemic analgesics for pain.<sup>3,50</sup> Drops and ointments are not always effective in resolving RCE.<sup>3,50</sup> In-office procedures such as punctal occlusion to enhance the tear film are also considered conventional standard of care, although complications can occur, including epiphora, conjunctival irritation, extrusion, and canaliculitis. Other surgical options include anterior



stromal puncture and phototherapeutic keratectomy (PTK), but these are more invasive and can also involve complications such as scarring, unwanted astigmatism, and hyperopic shifts.<sup>3,50</sup>

#### How CAM-C treats RCE

CAM-C protects the cornea from further abrasion and simultaneously enhances epithelial regrowth (Figure 7).<sup>50</sup>



**Figure 7.** RCE before and after a debridement with application of CAM-C. Reprinted with permission from Sheha H, Tighe S, Cheng AM, Tseng SC. Amniotic membrane transplantation. In *Expert Techniques in Ophthalmic Surgery*, 1st edition. New Delhi, India: JAYPEE Publishers;2015:167-75.

#### Optimal Place of CAM-C in Revised Treatment Protocol of RCE

CAM-C is appropriate for RCE patients who have been compliant with but failed other conservative RCE treatments. Many of these patients will be referred from other comprehensive eyecare professionals—ophthalmologists or optometrists—who have tried various conventional therapies.

Any patient with RCE who needs an epithelial keratectomy/debridement should also be treated with CAM-C immediately following the debridement. The goal with RCE treatment is to debride the unhealthy epithelium and generate a new, healthier basement membrane/Bowman's layer complex while also controlling inflammation and preventing scars from forming. In order to determine how much, if any, of the epithelium needs to be debrided before placing CAM, the clinician should apply anesthetic and then gently push against the cornea with a cellulose sponge to identify the entire area of poorly attached or loose epithelium that would warrant removal. Nonadherent epithelium often covers a far broader area than initially suspected, and debridement commonly removes all of the epithelium centrally as well as peripherally right up to the limbus-based stem cells.

RCE stands at the junction between inflammation-induced and defect-based disease. Unlike BCL, CAM-C confers an antiinflammatory effect without inducing hypoxia, allowing the epithelium to heal more effectively. RCE, however, may also be associated with EBMD, which is a disease not of the epithelium but of the underlying basement membrane—specifically of the hemidesmosomes on the coalesced footplates of the basal epithelial layer.<sup>50,51</sup> For these EBMD-based RCE patients, a debridement and CAM-C should be standard of care when medical therapy is inadequate to control the condition, as CAM-C creates an environment that allows for the reformation of hemidesmosomes and the coalescence of epithelial footplates. CAM-C can also be used without debridement in patients with RCE who do not have a sloughing epithelium but who do have moderate topographic abnormalities and DED.

## Case Presentation: CAM-C for Treatment of RCE (Courtesy of Dr. Salinger)

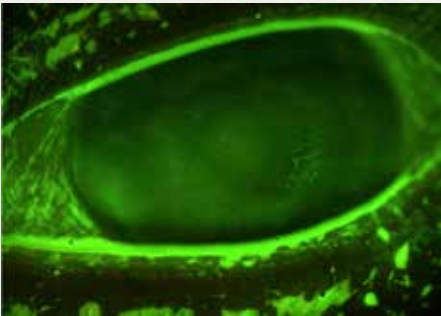
73-year-old white male.

### HISTORY

- Multiple episodes of RCE (OU) beginning prior to 2005
- Multiple treatments over several years:
  - Frequent lubrication with AT, hypertonic saline, bedtime ointment
  - Discontinued use of ceiling fans at bedtime
  - Sleep mask
  - Omega-3/6 supplements
  - Topical steroids, antibiotics, and nonsteroidal antiinflammatory drugs (NSAIDs)
  - Cyclosporine/lifitegrast

### EXAMINATION

OS 9/18/2015



**Figure 8.** Area slightly temporal to pupil of irregular epithelium, revealing a negative fluorescein staining pattern and multiple intra-epithelial microcysts (IEMC).

### DIAGNOSIS:

- RCE

### TREATMENT

- Maintained on AT, bedtime ointment, omega-3/6 supplements
- Trials with BCL, exchanging every 3 to 4 weeks for 3 months
- Superficial keratectomy (OD) on 4/29/10
- Multiple symptomatic recurrences, small and large, mild and severe, at relatively short intervals over many years. Treatment with CAM-C (PROKERA Slim; Bio-Tissue, Miami, FL) and BCL (OS) for 1 week starting on 9/14/18. No recurrent episodes noted at 9 months after CAM-C treatment application.

### FOLLOW-UP

- Occasional, mild symptoms of RCE (OD) with no significant recurrences
- No episodes or symptoms of RCE (OS) for the past 9 months
- Smoother epithelium, barely trace evidence of a negative fluorescein staining pattern with trace IEMC

If RCE is present with an active infection, then we follow the protocol outlined above for infectious keratitis: that is, we use CAM-C as soon as possible after the etiology of the infection is determined and/or a response to initial antimicrobial therapy is observed.

## TREATMENT PROTOCOLS FOR INFLAMMATION-INDUCED CORNEA-INVOLVED OCULAR SURFACE DISEASE

### EBMD

#### BACKGROUND

EBMD is very common, occurring in up to 15% of the population.<sup>50</sup> It is often associated with RCE. While it can be acutely painful, more often patients with EBMD are asymptomatic, without associated pain, foreign body sensation, photophobia, or discomfort. Nevertheless, EBMD can cause irregular astigmatism; combined with a less-than-ideal tear film, EBMD may contribute symptoms of fluctuating visual quality and function. Moreover, preexisting untreated EBMD can have a substantial negative impact on cataract and refractive surgery outcomes. Because it can cause topographic abnormalities, EBMD often makes preoperative measurements unreliable, which, in turn, causes patients to be unhappy with their postoperative outcomes, especially if they have been implanted with a presbyopia-correcting intraocular lens (IOL). If patients become symptomatic after cataract or refractive surgery, they are likely to blame the surgeon for their EBMD.

#### Limitations of Conventional Standard of Care

When symptomatic, EBMD is initially treated with lubricants, hypertonic solutions, and BCLs, but these treatments are not always effective.<sup>52</sup> In cases where drops or BCLs are ineffective, patients with EBMD can opt for more invasive procedures such as stromal puncture, PTK, or epithelial debridement.<sup>52</sup>

Furthermore, debridement alone does nothing to address the inflammatory basis of EBMD and promote healing. As noted above, EBMD is not a disease of the epithelium but of the underlying basement membrane—specifically of the hemidesmosomes on the coalesced footplates of the basal epithelial layer.<sup>50,51</sup>

#### How CAM-C Treats EBMD

CAM-C protects damaged corneal tissue while simultaneously allowing for regenerative wound healing.<sup>50</sup>

#### Optimal Place of CAM-C in Revised Treatment Protocol of EBMD

CAM-C should be used in any patient with visually or topographically significant EBMD. Specifically, on topographic mapping, if the EBMD creates drop-out zones or irregular islands in the topography, or increases the root-mean-square (RMS) value above 0.4, the patient should be treated with CAM-C.

In addition, patients whose EBMD appears to be turning into RCE should be treated proactively with CAM-C, as the two conditions have a common pathophysiology.

The time to use CAM-C for patients with EBMD who are contemplating refractive cataract surgery is after a superficial keratectomy and before surgery.

## Dry Eye Disease & Neurotrophic Keratitis

#### BACKGROUND

DED is one of the most common ocular surface disorders globally and in the United States, with a worldwide prevalence of 5% to 34%.<sup>53,54</sup> Moderate to severe DED—Dry Eye Workshop (DEWS) Score 3 to 4—is associated with MGD and, in later-stage cases, NK, corneal scarring, and corneal perforation.<sup>36,55</sup>

#### Limitations of Conventional Standard of Care

The conventional standard of care recommends first treating severe DED with AT, topical antiinflammatory medications including cyclosporine or lifitegrast, topical corticosteroids,

and antibiotics when epithelial defects are diagnosed.<sup>55</sup> These initial treatments may not be successful in more severe forms of DED, and finding the right option may be difficult. One major challenge in treating DED is recognizing that it often requires multiple concomitant treatments. A patient with more severe DED may need cyclosporine, steroids, lifitegrast, lid hygiene, nutritional supplements, punctal plugs, and CAM-C, for example.

Patients with severe DED are sometimes treated with BCL, but many experts avoid this option whenever

## Case-Control Series: CAM-C for Treatment of EBMD (Courtesy of Dr. Desai)

10 patients with bilateral EBMD or Salzmann's nodular degeneration (SND).

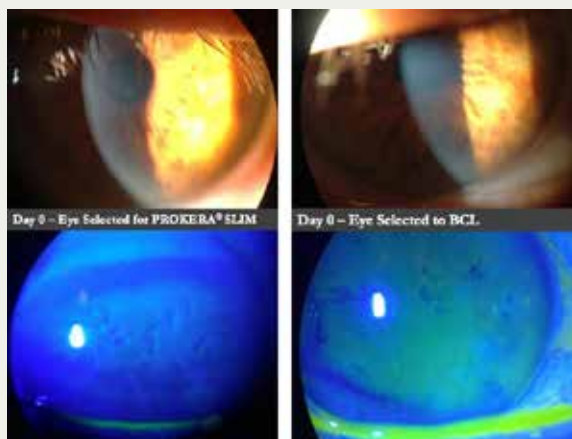
### TREATMENT PLAN

- Superficial keratectomy OU performed at slit lamp
- Eyes with more severe disease received CAM-C (PROKERA® Slim; Bio-Tissue, Miami, FL)
- Eyes with less severe disease received BCL, previous gold standard
- Eyes with equal disease randomized to CAM-C or BCL
- CAM-C and BCL retained for 1 week
- Both eyes received topical antibiotic, steroid, and NSAID regimen post-op

### FOLLOW-UP

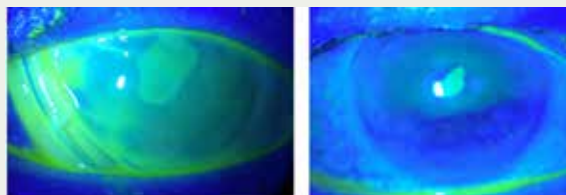
- Best-corrected visual acuity (BCVA) checked at day 0 and month 1
- Adverse events were monitored throughout
- Exam and photos at days 0, 3, 5, 7 and month 1
- Haze and scar assessed after removal of membrane and BCL at day 7

### DAY 0

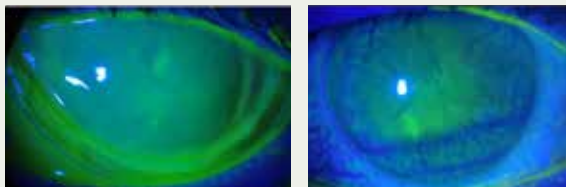


**Figure 9.** In this patient, the right eye had central EBMD and was treated with CAM-C; the left eye had more peripheral disease and was treated with a BCL.

### DAY 3

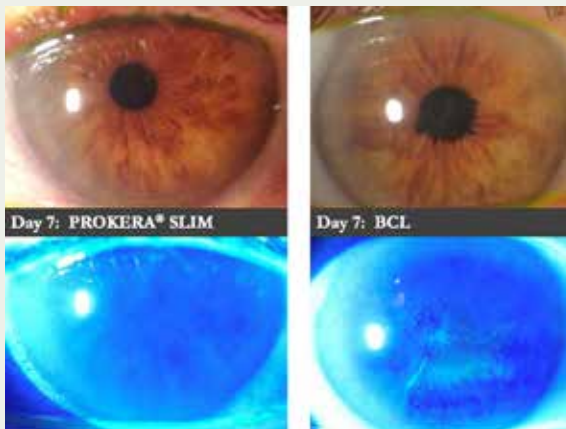


### DAY 5



**Figure 10.** By day 3, the start of re-epithelialization was seen in both eyes, with perhaps more progress in the eye treated with BCL. By day 5, however, the eye treated with CAM-C had a visibly smoother, healthier-looking epithelium.

### DAY 7



**Figure 11.** By day 7, the quality of healing was significantly greater in the CAM-C-treated eye, which had a smooth, intact epithelium. In contrast, the BCL-treated eye continued to show evidence of underlying inflammation, despite the steroid, as well as haze and scar. Iris detail, which is an indicator of corneal clarity, was also significantly better in the CAM-C-treated eye.

possible because BCL can induce hypoxia and inflammatory cascades on the ocular surface, which is already inflamed in DED patients. For refractory patients with severe DED, the conventional standard of care may recommend more invasive treatments, such as punctal plugs or surgical procedures such as cautery occlusion.<sup>53,55,56</sup>

*How CAM-C Treats Moderate to Severe DED*

In a prospective study of 10 patients with moderate to severe DED, treatment with CAM-C (PROKERA®, Bio-Tissue) was associated with a dramatic reduction of all signs and symptoms at 1 month, which was maintained out to 3 months (the duration of the study). In addition to symptomatic relief and improved vision, CAM-C regenerated corneal nerves as measured by increased nerve density on confocal microscopy and increased corneal sensitivity, attesting to its regenerative mechanism of action.<sup>15</sup>

**Case Presentation: CAM-C for Treatment of Severe DED (Courtesy of Dr. Milner)**

56-year-old white male referred for LASIK evaluation on 12/28/17.

**HISTORY**

- Retinal detachment (OD) treated with pars plana vitrectomy, scleral buckle, and gas
- Cataract surgery (OD) on 6/29/17
- Ocular medications at the time of presentation included AT, nepafenac qd, and difluprednate qd (OD)

**EXAMINATION**

- VA: 20/100 -2 OD with manifest refraction (MR); 20/20 OS with MR
- Schirmer test: 9 OD, 7 OS after 5 minutes without anesthesia
- Lids: 2+ MGD with 50% MG dropout
- Conjunctiva: papillary reaction OU
- Cornea: 3+ punctate staining OD; map-dot-fingerprint (MDF) dystrophy OU; corneal sensation 0-1/4 OD, 4/4 OS
- Topography: Irregular astigmatism OD

**DIAGNOSIS**

- MGD, NK, severe DED

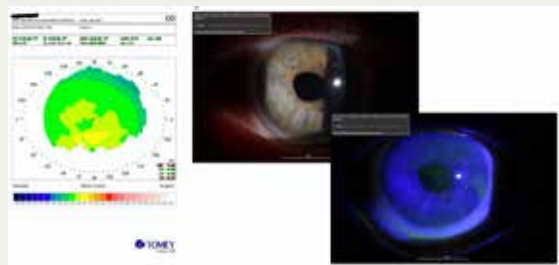
**TREATMENT**

- Initiated 12/28/17
  - Cyclosporine BID OU
  - Punctal plug right lower lacrimal (RLL) punctum
  - Erythromycin ointment OU qhs

- Discontinued nepafenac

**FOLLOW-UP**

- 2/6/18: VA 20/70 MR OD; upper plug placed OD
- 3/14/18: VA 20/80; trace 1+ punctate epithelial keratopathy (PEK); CAM-C (PROKERA®, Bio-Tissue) placed OD for 6 days
- 10/22/18: VA 20/30 MR; 1-2+ PEK; lifitegrast added to cyclosporine
- 4/8/19: VA 20/25 MR; rare PEK (almost none); sensation 1/4



**Figure 12.** Treating the ocular surface with CAM-C helped improve the topography, eliminate punctate staining, and improve corneal sensation by regenerating nerves. The patient's vision improved from 20/100 initially to 20/30 after treatment with CAM-C, and eventually to 20/25.

In a larger retrospective study of 97 eyes of 84 patients with DED refractory to other treatments, use of a single, 5- to 7-day CAM-C (PROKERA®; Bio-Tissue, Miami, FL) was associated with improved ocular surface health in 88% of patients tested—as evidenced by resolution of corneal punctate staining and improvement of visual symptoms—and a statistically significant reduction in DEWS scores. As with the smaller prospective study, there was a dramatic reduction of all DED signs and symptoms at 1 month, out to 3 months, demonstrating the treatment's duration of effect.<sup>54</sup>

#### *Optimal place of CAM-C in Revised Treatment Protocol for Moderate to Severe DED*

CAM-C can be used very effectively as an intervention for moderate to severe DED. Similar to the way steroids can be used as induction therapy to “jump-start” cyclosporine or lifitegrast, we use CAM-C as a potent, rapid-acting, adjunctive therapy for DED after first-line therapies have failed. Because CAM-C has a better safety profile than topical steroids, we recommend it in lieu of topical steroids as induction therapy in moderate to severe DED, particularly for at-risk patients with glaucoma and other concomitant diseases known to exacerbate DED. CAM-C can help “reset” and normalize the ocular surface so that longer-term therapies such as cyclosporine or lifitegrast can work better and keep the disease under better control. Patients with “recalcitrant” DED—severe DED that doesn't respond adequately to first-line therapies—are ideal candidates for CAM-C, but we use CAM-C whenever inflammation and punctate epithelial keratitis are

present, as well as for patients with coexisting DED and neurotrophic corneas.

CAM-C, however, is more than just an acute intervention: as numerous studies have shown, a 5- to 7-day course of CAM-C continues to provide benefits for DED for at least 3 months and up to 9 months.<sup>16,54</sup>

#### *Neurotrophic Keratitis*

In addition, because CAM-C helps regenerate corneal nerves, it provides a unique benefit for patients with severe DED, who may have diminished sensation and a reduced blink reflex. As DEWS II emphasizes, DED can lead to neurosensory abnormalities and a neurotrophic cornea.<sup>56</sup> These patients may not even know when instillation of ATs would be beneficial because of the reduced sensation.

There is a strong correlation between DED severity and the loss of corneal nerves in NK, a degenerative disease caused by damage to the trigeminal nerve. The most common causes of NK are herpetic infections, such as with herpes simplex, varicella zoster, or diabetes. CAM-C is a very effective treatment for this serious disease and can be used first-line. Cenegermin (Oxervate; Dompé farmaceutici, Milan, Italy), a recombinant form of human nerve growth factor, was recently approved by the FDA for NK and can be used as an adjunctive maintenance treatment to continue to normalize the cornea once CAM-C has been applied as induction therapy.

## Pre-surgical Ocular Surface Optimization

### **BACKGROUND**

Any cornea-involved ocular disease, but most commonly DED and EBMD, can reduce visual quality and adversely affect the biometric, refractive, keratometric, and topographic measurements taken before refractive cataract surgery.<sup>57</sup> As a result, cornea-involved ocular disease can negatively impact intraocular lens (IOL) power selection and recommendations for advanced technology IOLs.<sup>58,59</sup> A candidate for an advanced technology IOL may be deprived of the opportunity for such a lens because of untreated cornea-involved ocular disease.

Among candidates for cataract surgery, up to 75% may have DED and 59% may have blepharitis, both of which diminish corneal surface integrity and therefore readiness for surgery.<sup>60</sup> EBMD, which occurs in up to 15% of the population, can also affect postsurgical outcomes, potentially leading to corneal haze and RCE.<sup>50,60</sup>

In addition, ocular surgery can exacerbate or induce cornea-involved ocular surface disease, leading to worsened vision, increased symptoms, and overall dissatisfaction postoperatively.<sup>57</sup>

Treating patient signs and symptoms to restore ocular surface health prior to surgery is important not only for addressing patient comfort but also for preventing perioperative infection and obtaining optimal pre-surgical measurements.<sup>61</sup> By treating cornea-involved ocular surface disease preoperatively, postoperative visual outcomes and patient satisfaction can be significantly improved.<sup>57</sup>

### *Limitations of Conventional Standard of Care*

Conventional presurgical therapy, which usually consists of AT and other supportive measures, requires patient investment and compliance to be successful.<sup>61</sup> The ASCRS Cornea Clinical Committee developed a new consensus-based practical diagnostic algorithm to aid surgeons in efficiently diagnosing visually significant ocular surface

disease before any form of refractive surgery is performed. The algorithm recommends application of CAM-C several weeks prior to surgery depending on the indication.<sup>57</sup>

### *How CAM-C Works to Optimize the Ocular Surface Before Surgery*

CAM-C, being rich in collagen type IV, fibronectin, and laminin,<sup>6</sup> can help rebuild the basement membrane once a superficial keratectomy is performed<sup>45</sup> and thus yield more accurate pre-surgical readings. It can be applied after a superficial keratectomy for RCE or EBMD patients 4 to 6 weeks prior to surgery. By rapidly optimizing ocular surface health, CAM-C is the most time-efficient option prior to surgery. Additionally, we previously mentioned that CAM-C can help “reset” and normalize the ocular surface so that longer-term therapies such as cyclosporine or lifitegrast can work better and keep the disease under better control.

### *Optimal Place of CAM-C in Revised Treatment Protocol for Pre-surgical Ocular Surface Optimization*

Any pre-surgical patient with EBMD that requires epithelial removal or with severe DED should be treated pre-surgically with CAM-C. In addition, any patient with an RMS value of 0.4 or greater should be treated with CAM-C before cataract surgery. However, different thresholds are appropriate for different topographic analyzers. For example, for those practices utilizing an optical path difference (OPD) corneal analyzer, we recommend pre-surgical CAM-C treatment for patients with a corneal coma higher-order aberration value of 0.3 or greater.

Pre-surgical treatment with CAM-C should also be considered when the surgeon or technician encounter difficulties obtaining a reliable pre-op measurement or when inconsistencies arise between multiple confirmatory methods of topographic or keratometric analysis.

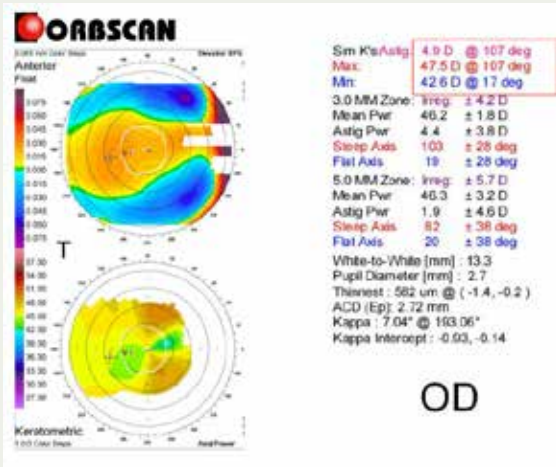
## Case Presentation: How CAM-C Works to Optimize the Ocular Surface Before Surgery (Courtesy of Dr. Desai)

Female patient presented for cataract evaluation, pre-booked for surgery the following day

### HISTORY

- Astigmatism
- Followed by a cornea specialist for several years
- Examination
- Significant EBMD OU

### PRESURGICAL CASE 2: BEFORE KERATECTOMY




**Figure 13.** The EBMD affected the biometry seen here.

### TREATMENT

- Postponed surgery
- Superficial keratectomy
- CAM-C therapy (PROKERA®, Bio-Tissue, Miami, FL)

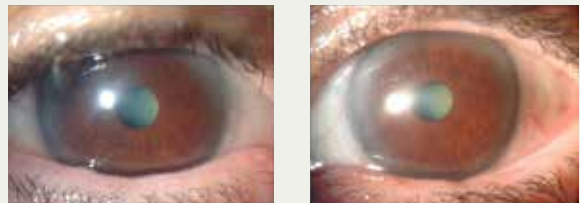### PRE-SURGICAL FOLLOW-UP

- Day 3: completely re-epithelialized



**Figure 14.** Complete re-epithelialization was confirmed by day 3 following superficial keratectomy and CAM-C treatment. Note that assessment of accelerated, high-quality, regenerative healing is possible without removal of the CAM.

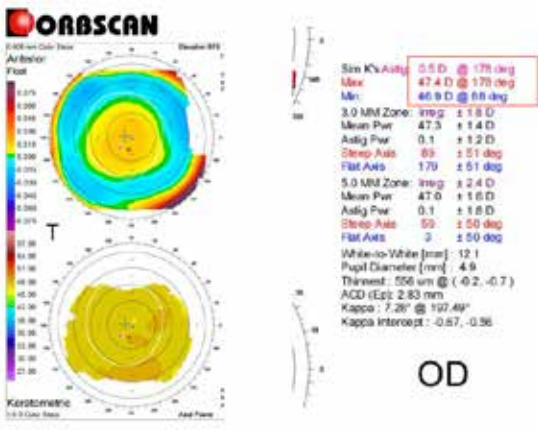
- Week 4: No scar, haze, or fibrosis



**Figure 15.** By week 4 following superficial keratectomy and regenerative CAM-C treatment, the patient's keratitis and EBMD were resolved and no scar, haze, or fibrosis were evident. The ocular surface was optimized for cataract surgery planning.

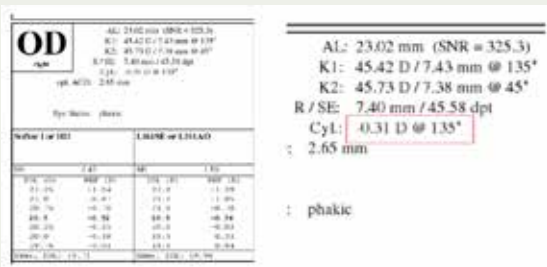
- Repeated biometry





**Figure 16.** Biometry was repeated at week 4. The patient's topographies were completely normalized, and the astigmatism changed from 4.7 or 4.9 diopters to 0.5 diopters at a significantly different axis.

- Re-performed biometry and scheduled for surgery



**Figure 17.** The IOL master showed 0.3 diopters of astigmatism, in contrast to the 4.9 diopters from the original biometry readings. IOL selection power changed from 22 diopters to 19.7 (2.25 diopter change). Originally a poor candidate for a monofocal IOL and someone for whom a toric IOL would have been unnecessary, the patient became a good candidate for a presbyopia-correcting or an extended depth-of-focus IOL thanks to the superficial keratectomy and CAM-C treatment.

**SURGERY**

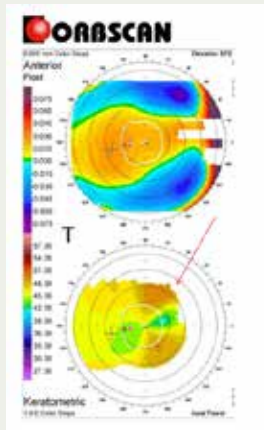
- Removal of cataract
- Implantation of extended depth-of-focus IOLs

**POST-SURGICAL FOLLOW-UP**

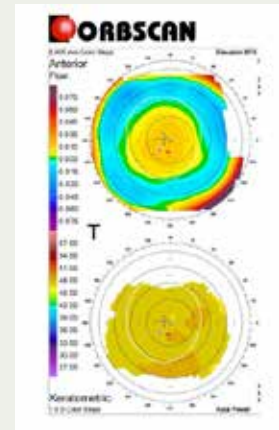
Post-op day 1 vision was 20/40 OD and 20/30 OS

- Prior to superficial keratectomy and CAM-C treatment, the patient's vision was 20/80 OD and 20/50 OS, suggesting a 3-line improvement in vision from the pre-surgical treatment alone.
- Post-op day 7: 20/25+ and J2+ OU
- 6 weeks post-op: YAG laser capsulotomy
- After capsulotomy: 20/20+ and J2+ OU, which were the intended refractive targets
- Patient is now largely spectacle independent and enjoys better vision than would have been achieved without CAM-C treatment to optimize the ocular surface before surgery.

**BEFORE**



**AFTER**



**Figure 18.** Dramatic change in topographies from pre- to post-treatment.

## CONCLUSIONS AND CLINICAL PEARLS

Based on our collective experience with CAM-C for treating corneal-involved ocular surface diseases and pre-surgical optimization of the ocular surface, we have revised current treatment protocols to include the use of CAM-C, a truly disease-modifying therapy, at earlier stages of disease. CAM-C can only be provided with cryopreserved amniotic membrane.

The following clinical pearls provide a succinct, practical summary of this consensus guideline. They are designed to be separated from the rest of the guideline and saved for future reference.

### *Persistent Epithelial Defect*

- Any patient with PED is a good candidate for CAM-C.
- CAM-C should be used first-line for an acute epithelial defect, proximal to the point of initial injury, when the risk of persistency is high.
- CAM-C should be considered early for epithelial defects that present a high risk for delayed healing and scarring.

### *Corneal Ulcer/Infectious Keratitis*

- Many patients with corneal ulcer/infectious keratitis are good candidates for CAM-C.
- Use CAM-C as soon as possible after identifying the origin of the corneal ulcer/infectious keratitis, particularly when the ulcer is central, large, necrotic, or associated with significant inflammation.
- CAM-C can be used on an active viral or bacterial infection because of its antimicrobial properties and because the infection can be monitored with fluorescein through the AM. In patients with a more active infection, CAM may possibly warrant replacement if it turns from translucent to opaque or dissolves partially (Swiss cheese holes) or completely.
- In patients with suspected protozoan or fungal keratitis, consider the use of CAM-C only after a diagnosis can be confirmed by culture, Gram stain, confocal microscopy—or, more importantly, after a response to topical therapy is observed.

### *Recurrent Corneal Erosion*

- For patients who have RCE and a sloughing epithelium—whether EBMD- or trauma-

based—a debridement and treatment with CAM-C should be strongly considered early in the course of the disease process.

- CAM-C can also be used without debridement in RCE without a sloughing epithelium but with moderate topographic abnormalities and DED.
- If RCE presents alongside an active infection, use CAM-C as soon as possible after identifying the etiology/antimicrobial sensitivities and controlling the infectious process.

### *Epithelial Basement Membrane Dystrophy*

- CAM-C should be used in any patient with visually or topographically significant EBMD.
- Patients whose EBMD appears to be turning into RCE should also be treated with CAM-C.

### *Moderate to Severe Dry Eye Disease*

- The optimal use of CAM-C for persistent, highly symptomatic, or recalcitrant DED is as an adjunctive intervention after first-line therapies have proved inadequate to control the symptoms and signs of ocular surface disease.
- CAM-C may be used in place of steroids, in addition to steroids, or as a steroid-sparing agent for induction therapy in DED as long-term topical anti-inflammatories (eg, cyclosporine, lifitegrast) begin to work.

### *Neurotrophic Keratitis*

- CAM-C should be used as a first-line treatment to regenerate corneal nerves damaged in NK.
- When used as induction therapy, CAM-C may be followed by maintenance treatment with a recently FDA-approved recombinant form of human nerve growth factor.

### *Prior to Refractive Cataract Surgery*

- Any pre-surgical patient with EBMD, especially those who require epithelial removal, or with more severe DED, may be treated before refractive, cataract, or refractive cataract surgery with CAM-C.
- Consider pre-surgical treatment with CAM-C any time a technician has difficulty obtaining a pre-op measurement or when inconsistencies are found between multiple methods of topographic or keratometric analyses.

## REFERENCES

- Gupta S, Gupta P, Sayegh R. Healing a persistent corneal epithelial defect. *EyeNet*. August 2014. American Academy of Ophthalmology. <https://www.aao.org/eyenet/article/healing-persistent-corneal-epithelial-defect>. Accessed July 19, 2019.
- Afshari NA, Mah FR, Tu EY, Tuli SS. Confronting corneal ulcers. *EyeNet*. July 2012. American Academy of Ophthalmology. <https://www.aao.org/eyenet/article/confronting-corneal-ulcers>. Accessed July 19, 2019.
- Hemmati HD, Thakrar R. Treatment of recurrent corneal erosions. *EyeNet*. 2013. American Academy of Ophthalmology. <https://www.aao.org/eyenet/article/treatment-of-recurrent-corneal-erosions>. Accessed July 23, 2019.
- Rubins D, Pathak AK, Feldman BH. Bandage contact lenses after refractive surgery. *EyeWiki*. 2015. American Academy of Ophthalmology. [https://eyewiki.aao.org/Bandage\\_Contact\\_Lenses\\_After\\_Refractive\\_Surgery](https://eyewiki.aao.org/Bandage_Contact_Lenses_After_Refractive_Surgery). Accessed September 25, 2019.
- Tseng SC. HC-HA/PTX3 Purified from amniotic membrane as novel regenerative matrix: insight into relationship between inflammation and regeneration. *IOVS*. 2016;57(5):1-8.
- Jirsova K, Jones GLA. Amniotic membrane in ophthalmology: properties, preparation, storage and indications for grafting-a review. *Cell Tissue Bank*. 2017;18(2):193-204.
- Röck T, Bartz-Schmidt KU, Landenberger J, Bramkamp M, Röck D. Amniotic membrane transplantation in reconstructive and regenerative ophthalmology. *Ann Transplant*. 2018;23:160-65.
- Watson CT, Breden F. The immunoglobulin heavy chain locus: genetic variation, missing data, and implications for human disease. *Genes and Immunity*. 2012;13: 363-73.
- Cooke M, Tan EK, Mandrycky C, He H, O'Connell J, Tseng SC. Comparison of cryopreserved amniotic membrane and umbilical cord tissue with dehydrated amniotic membrane/chorion tissue. *J Wound Care*. 2014;23(10):465-74, 476.
- Mcgaughy AG, Gupta PK. In-office use of amniotic membrane. *EyeNet*. 2015 Feb;31-32. <https://www.aao.org/eyenet/article/in-office-use-of-amniotic-membrane>. Accessed November 8, 2019.
- AmnioGraft. <https://www.biotissue.com/amniograft>. Accessed November 8, 2019
- Wirostko B, Rafii M, Sullivan DA, Morelli J, Ding J. Novel therapy to treat corneal epithelial defects: a hypothesis with growth hormone. *Ocul Surf*. 2015;13(3):204-212.
- Jeng BH, Dupps WJ Jr. Autologous serum 50% eyedrops in the treatment of persistent corneal epithelial defects. *Cornea*. 2009;28(10):1104-8.
- Moore M, Connolly SY, Wang MX. Amniotic membrane contact lens: effectiveness in treating keratoepithelial defects due to wide range of ocular surface disease. Paper presented at 2014 annual meeting of the American Society of Cataract and Refractive Surgery (ASCRS); April 25-29, 2014; Boston, MA.
- John T, Tighe S, Sheha H, et al. Corneal nerve regeneration after self-retained cryopreserved amniotic membrane in dry eye disease. *J Ophthalmol*. Published online Aug 15, 2017. doi: 10.1155/2017/6404918.
- Morkin MI, Hamrah P. Efficacy of self-retained cryopreserved amniotic membrane for treatment of neuropathic corneal pain. *Ocul Surf*. 2018;16(1):132-38.
- Pachigolla G, Prasher P, Di Pascuale MA, McCulley JP, McHenry JG, Mootha VV. Evaluation of the role of ProKera in the management of ocular surface and orbital disorders. *Eye Contact Lens*. 2009; 35(4):172-75.
- Huang Y, Sheha H, Tseng SC. Self-retained amniotic membrane transplantation for recurrent corneal erosion. *J Clin Exp Ophthalmol*. 2013;4:272. doi:10.4172/2155-9570.1000272
- Shay E, Khadem JJ, Tseng SC. Efficacy and limitation of sutureless amniotic membrane transplantation for acute toxic epidermal necrolysis. *Cornea*. 2010. 29(3):359-61.
- Kheirkhah A, Casas V, Raju VK, Tseng SC. Sutureless amniotic membrane transplantation for partial limbal stem cell deficiency. *Am J Ophthalmol*. 2008.145(5):787-94.
- Ashraf H, Font K, Powell C, Schurr M. Antimicrobial activity of an amnion-chorion membrane to oral microbes. *Int J Dent*. 2019;2019:1269534.
- Gholipourmalekabadi M, Bandehpour M, Mozafari M, Hashemi A, Ghanbarian H, Sameni M, et al. Decellularized human amniotic membrane: more is needed for an efficient dressing for protection of burns against antibiotic-resistant bacteria isolated from burn patients. *Burns*. 2015;41(7):1488-97.
- Kjaergaard N, Hein M, Hyttel L, Helmig RB, Schönheyder HC, Uldbjerg N, et al. Antibacterial properties of human amnion and chorion in vitro. *Eur J Obstet Gynecol Reprod Biol*. 2001;94(2):224-9.
- Mao Y, Hoffman T, Singh-Varma A, Duan-Arnold Y, Moorman M, Danilkovitch A, et al. Antimicrobial peptides secreted from human cryopreserved viable amniotic membrane contribute to its antibacterial activity. *Sci Rep*. 2017;7(1):13722.
- Mao Y, Hoffman T, Johnson A, Duan-Arnold Y, Danilkovitch A, Kohn J. Human cryopreserved viable amniotic membrane inhibits the growth of bacteria associated with chronic wounds. *J Diabetic Foot Complications*. 2016;8:23-30.
- Mao Y, Singh-Varma A, Hoffman T, Dhall S, Danilkovitch A, Kohn J. The effect of cryopreserved human placental tissues on biofilm formation of wound-associated pathogens. *J Funct Biomater*. 2018; 9(1):3.
- Marsit NM, Sidney LE, Britchford ER, McIntosh OD, Allen CL, Ashraf W, et al. Validation and assessment of an antibiotic-based, aseptic decontamination manufacturing protocol for therapeutic, vacuum-dried human amniotic membrane. *Sci Rep*. 2019;9(1):12854.
- Mencucci R, Paladini I, Menchini U, Gicquel JJ, Dei R. Inhibition of viral replication in vitro by antiviral-treated amniotic membrane. Possible use of amniotic membrane as drug-delivering tool. *Br J Ophthalmol*. 2011;95(1):28-31.
- Mencucci R, Menchini U, Dei R. Antimicrobial activity of antibiotic-treated amniotic membrane: An in vitro study. *Cornea*. 2006;25(4):428-31.

30. Palanker ND, Lee CT, Weltman RL, Tribble GD, van der Hoeven R, Hong J, et al. Antimicrobial efficacy assessment of human derived composite amnion-chorion membrane. *Sci Rep*. 2019;9(1):15600.
31. Robson MC, Krizek TJ. The effect of human amniotic membranes on the bacteria population of infected rat burns. *Ann Surg*. 1973;177(2):144-9.
32. Šket T, Ramuta TŽ, Starčič Erjavec M, Kreft ME. Different effects of amniotic membrane homogenate on the growth of uropathogenic *Escherichia coli*, *Staphylococcus aureus* and *Serratia marcescens*. *Infect Drug Resist*. 2019;12:3365-75.
33. Tehrani FA, Ahmadiani A, Niknejad H. The effects of preservation procedures on antibacterial property of amniotic membrane. *Cryobiology*. 2013;67(3):293-8.
34. Zare-Bidaki M, Sadrinia S, Erfani S, Afkar E, Ghanbarzade N. Antimicrobial Properties of Amniotic and Chorionic Membranes: A Comparative Study of Two Human Fetal Sacs. *J Reprod Infertil*. 2017;18(2):218-24.
35. Mescher A. Macrophages and fibroblasts during inflammation and tissue repair in models of organ regeneration. *Regeneration*. 2017;4:39-53.
36. Sacchetti M, Lambiasi A. Diagnosis and management of neurotrophic keratitis. *Clin Ophthalmol*. 2014;8:571-9.
37. Bartolomei A, Kozak A, Feldman BH, et al. Bacterial keratitis. EyeWiki. 2019. American Academy of Ophthalmology. [https://eyewiki.aao.org/Bacterial\\_Keratitis](https://eyewiki.aao.org/Bacterial_Keratitis). Accessed October 9, 2019.
38. Austin A, Lietman T, Rose-Nussbaumer J. Update on the management of infectious keratitis. *Ophthalmology*. 2017;124(11):1678-89.
39. Sheha H, Liang L, Li J, Tseng SC. Sutureless amniotic membrane transplantation for severe bacterial keratitis. *Cornea*. 2009;28(10):1118-23.
40. Walter K, Tyler ME. Severe corneal toxicity after topical fluoroquinolone therapy: report of two cases. *Cornea*. 2006;25:855-57.
41. Lazzaro DR, Waring GO 4th, Liu M. Idiopathic superior keratectasia with spontaneous perforation treated with amniotic membrane transplantation. *Eye Contact Lens*. 2008;34(4):242-3.
42. Al-Mujaini A, Al-Kharusi N, Thakral A, and Wali UK. Bacterial keratitis: perspective on epidemiology, clinicopathogenesis, diagnosis and treatment. *Sultan Qaboos Univ Med J*. 2009; 9(2):184-95.
43. Lin A, Rhee MK, Akpek EK, et al, on behalf of the American Academy of Ophthalmology Preferred Practice Pattern Cornea and External Disease Panel. Bacterial Keratitis Preferred Practice Pattern®. 2019;126(1):P1-P55.
44. Srinivasan M, Mascarenhas J, Rajaraman R, et al; Steroids for Corneal Ulcers Trial Group. The steroids for corneal ulcers trial (SCUT): secondary 12-month clinical outcomes of a randomized controlled trial. *Am J Ophthalmol*. 2014;157(2):327-33.
45. Sheha H, Tighe S, Cheng AM, Tseng SC. Amniotic membrane transplantation. In *Expert Techniques in Ophthalmic Surgery*, 1st edition. New Delhi, India: JAYPEE Publishers;2015:167-75.
46. Kessler E, Mondino BJ, Brown SI. The corneal response to *Pseudomonas aeruginosa*: histopathological and enzymatic characterization. *Invest Ophthalmol Vis Sci*. 1977;16(2):116-25.
47. Hao JL, Nagano T, Nakamura M, Kumagai N, Mishima H, Nishida T. Effect of galardin on collagen degradation by *Pseudomonas aeruginosa*. *Exp Eye Res*. 1999;69(6):595-601.
48. Resch MD, Resch BE, Cszimazia E, et al. Drug reservoir function of human amniotic membrane. *J Ocul Pharmacol Ther*. 2011;27(4):323-6.
49. Holland GN, Donzis PB. Rapid resolution of early Acanthamoeba keratitis after epithelial debridement. *Am J Ophthalmol*. 1987;104(1):87-9.
50. Miller DD, Hasan SA, Simmons NL, Stewart MW. Recurrent corneal erosion: a comprehensive review. *Clin Ophthalmol*. 2019;13:325-35.
51. Pham LT, Goins KM, Sutphin JE, Wagoner, MD. Treatment of epithelial basement membrane dystrophy with manual superficial keratectomy. [EyeRounds.org](http://EyeRounds.org). 2010. University of Iowa Ophthalmology and Visual Sciences. <https://webeye.ophth.uiowa.edu/eyeforum/cases/78-EBMD-treatment.htm>. Accessed October 25, 2019.
52. Edell E, Bernfeld E, Woodward MA, Bunya V. Epithelial basement membrane dystrophy. EyeWiki. 2018. American Academy of Ophthalmology. [https://eyewiki.aao.org/Epithelial\\_basement\\_membrane\\_dystrophy](https://eyewiki.aao.org/Epithelial_basement_membrane_dystrophy). Accessed July 23, 2019.
53. Messmer EM. The pathophysiology, diagnosis, and treatment of dry eye disease. *Dtsch Arztebl Int*. 2015;112(5):71-82.
54. McDonald MB, Sheha H, Tighe S, et al. Treatment outcomes in the DRy Eye Amniotic Membrane (DREAM) study. *Clin Ophthalmol*. 2018;12:677-81.
55. American Academy of Ophthalmology Cornea/External Disease Panel. Preferred Practice Pattern Guidelines. Dry Eye Syndrome. San Francisco, CA: American Academy of Ophthalmology; 2013.
56. Craig JP, Nelson JD, Azar DT, et al. TFOS DEWS II Report Executive Summary. *Ocul Surf*. 2017 Oct;15(4):802-12.
57. Starr CE, Gupta PK, Farid M, et al. An algorithm for the preoperative diagnosis and treatment of ocular surface disorders. *JCRS*. 2019;45(5): 669-84.
58. Beckman K. Managing the unhappy cataract patient. *Cataract & Refractive Surgery Today*. 2011;Feb:65-68.
59. Epitropoulos AT, Matossian C, Berdy GJ, Malhotra RP, Potvin R. Effect of tear osmolarity on repeatability of keratometry for cataract surgery planning. *J Cataract Refract Surg*. 2015;41(8):1672-7.
60. Loh J. Importance of performing corneal topography before cataract surgery. *US Ophthalmic Review*. 2015;8(2):92-6.
61. Farid M. Cataract surgery success for dry eye patients. *Ophthalmology Management*. April 1, 2019. <https://www.ophthalmologymanagement.com/issues/2019/april-2019/cataract-surgery-success-for-dry-eye-patients>. Accessed July 23, 2019.

The foregoing references are all of the peer-reviewed publications addressing the topics discussed in this article as of March 11, 2020.