



Reimbursement Resource Guide



OCULAR

Table of Contents – Reimbursement Resource Guide

Medicare Coverage for Prokera® (CPT 65778) & Administrative Contractor (MAC) Jurisdictions Map (As of Nov. 2023)...	4
Links to Medicare Administrative Contractor (MAC) Jurisdictions	5
Need Answers to Questions? Contact The Pinnacle Health Group	5
Commercial Payor Coverage: Select major payors with coverage policies for Prokera.....	6
2024 CPT/ICD-10 Coding Sheets – Physician Fee Schedule (MPFS) / Facility Reimbursement (OPPS/ASC)	7-11
Common Modifiers Used in Ophthalmology	13
Proper Documentation / Documentation Requirements for Medicare Services	13
Sample CMS-1500 Claim form.....	12
Pinnacle Service Request form	15
Published Clinical Evidence: Punctate Keratitis (PK), Neurotrophic Keratitis (NK), Recurrent Corneal Erosion (RCE), Persistent Epithelial Defect (PED), Severe Dry Eye, Corneal Dystrophies, Corneal Ulcers, Corneal Abrasion, and EBMD/ABMD:	16-20
Sample Prior Authorization Request Letters	
Diagnosis: Punctate Keratitis (PK).....	21
Diagnosis: Neurotrophic Keratitis (NK)	24
Diagnosis: Recurrent Corneal Erosion (RCE)	27
Diagnosis: Persistent Epithelial Defect (PED).....	29
Diagnosis: Severe Dry Eye	31
Diagnosis: Corneal Abrasion	34
Diagnosis: Corneal Ulcer	36
Diagnosis: Epithelial Basement Membrane Dystrophy (EBMD)	36
Diagnosis: Hereditary Corneal Dystrophies	38
Sample Appeal Letter	
Denial Reason: Experimental & Investigational.....	42
Need additional assistance: The Pinnacle Health Group contact information.....	45

Disclaimer: The guidance contained in this document, dated January 2024, is provided for informational purposes only and represents no statement, promise, or guarantee by BioTissue Holdings Inc. or its operating subsidiaries including BioTissue Ocular Inc. and BioTissue Surgical Inc. (collectively BioTissue) concerning reimbursement, payment, charges. Similarly, all CPT codes and HCPCS codes are supplied for informational purposes only and represent no statement, promise, or guarantee by BioTissue that these code selections will be appropriate for a given service or that reimbursement will be made to the provider. This Guide is not intended to increase or maximize reimbursement by a Payor. BioTissue strongly recommends that you consult your individual Payor Organization regarding its relative and current reimbursement policies. For complete indications, contraindications, warnings, precautions, and adverse reactions, please reference full package insert.

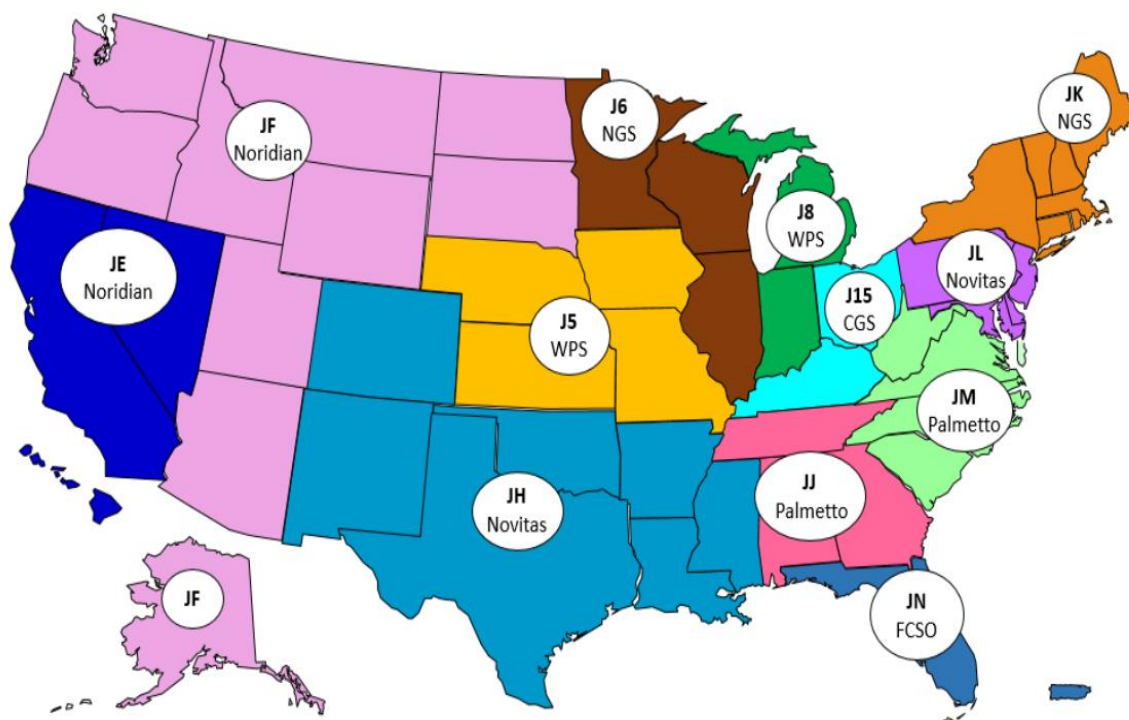
Procedure coding should be based upon medical necessity, procedures and supplies provided to the patient. Coding and reimbursement information is provided for educational purposes and does not assure coverage of the specific item or service in each case. BioTissue and The Pinnacle Health Group make no guarantee of coverage or reimbursement of fees. These payment rates are nationally unadjusted average amounts and do not account for differences in payment due to geographic variation. Contact your local Medicare Administrative Contractor (MAC) or CMS for specific information as payment rates listed are subject to change. To the extent that you submit cost information to Medicare, Medicaid, or any other reimbursement program to support claims for services or items, you are obligated to accurately report the actual price paid for such items, including any subsequent adjustments. CPT® five-digit numeric codes, descriptions, and numeric modifiers only are Copyright AMA.

Medicare Coverage for Prokera (CPT 65778)

Prokera® is Covered by Medicare in Every Jurisdiction

Medicare Administrative Contractor (MAC) Jurisdictions Map

(As of November 2023)



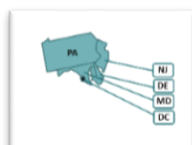
There are no NCDs or LCDs regarding Amniotic Membrane

First Coast retired their Amniotic Membrane LCD on March 25, 2022, and now there are no National Coverage Determinations (NCDs) or Local Coverage Determinations (LCDs) for the use of Amniotic Membrane placement on the ocular surface. Each jurisdiction will determine coverage on a case-by-case basis, based on documented medical necessity. Providers are encouraged to document medical necessity in the patient's record, including conservative care treatments that have failed.

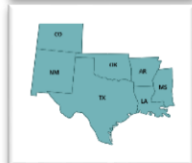Medicare only covers services that are reasonable and necessary. So those guidelines which dictate acceptable medical practice from other sources (peer reviewed literature, professional society protocols, etc.), would serve as potential sources of "reasonable and necessary" indications and practices in the event of an audit. Provider offices remain responsible for correct performance, coding, billing, and medical necessity under Medicare.

For additional jurisdiction-specific information, go to that MAC by clicking on the corresponding map or text box to be taken to the jurisdiction landing page. Additional information can be obtained on specific Jurisdiction pages.

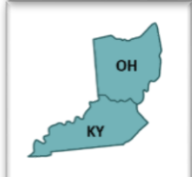Links to Medicare Administrative Contractor (MAC) Jurisdictions



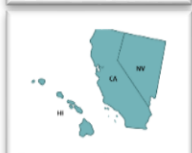Novitas JL: DE, DC, MD, NJ, & PA



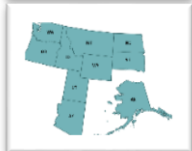Novitas JH: AR, CO, LA, MS, NM, OK, TX, Indian Health, & Veteran Affairs



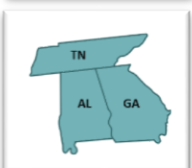CGS - J15: KY & OH



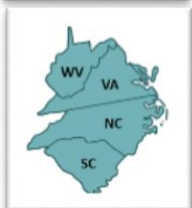Noridian JE: CA, HI, NV



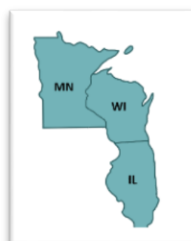Noridian JF: AK, AZ, ID, MT, ND, SD, OR, UT WA, & WY



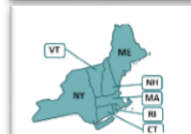Palmetto GBA JJ: TN, AL, & GA



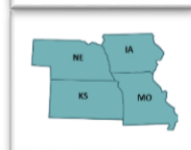Palmetto GBA JM: W VA, VA, NC, & SC



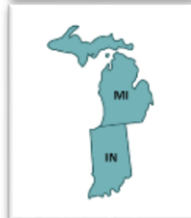NGS J6: IL, MN, & WI



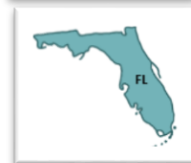NGS JK: ME, VT, NH, MA, RI, CT, & NY



WPS J5: NE, KS, IA, & MO



WPS J8: MI, & IN



First Coast FCSO - JN: (Florida, Puerto Rico & U.S. Virgin Islands)

If you have reimbursement questions, reach out to The Pinnacle Health Group:

If you have any additional questions regarding coding, coverage, and payment; or require assistance with pre-determination, prior authorization, or coverage appeals for a particular patient, please contact the BioTissue Reimbursement Hotline at 866-369-9290 or email biotissueocular@thepinnaclehealthgroup.com.

Commercial Payor Coverage

Prokera® is covered by Medicare, Medicaid, and most insurance companies for a wide variety of diagnoses and conditions. Check with your payor and payor contract to determine their coverage of specific procedures and codes. Remember, provider offices remain responsible for correct coding, billing, and the documentation of patient's medical necessity, for any billed codes. As the existence of a policy does not guarantee payment, it is recommended that prior authorization or pre-determination be acquired before moving ahead with the procedure.

Select major payors with coverage policies for Prokera:



Aetna – [Corneal Graft and Amniotic Membrane Transplantation, Limbal Stem Cell Transplantation, or Sural Nerve Grafting for Ocular Indications](#)



Anthem – [Allogeneic, Xenographic, Synthetic and Composite Products for Wound Healing and Soft Tissue Grafting – Medical Policy #: SURG.00011](#)



Humana – [Ocular Surface Disease Diagnosis and Treatments](#)



Blue Cross Blue Shield Federal Employee Plan (FEP) – [Z.01.149 Amniotic Membrane and Amniotic Fluid.pdf \(fepblue.org\)](#)

At the end of this Guide, you will find prior authorization letter templates to use with various diagnoses, and an appeal letter template.

If you have any additional questions regarding coding, coverage, and payment; or require assistance with pre-determination, prior authorization, or coverage appeals for a particular patient, please contact the BioTissue Reimbursement Hotline at 866-369-9290 or email biotissueocular@thepinnaclehealthgroup.com.

Procedure coding should be based upon medical necessity, procedures and supplies provided to the patient. Coding and reimbursement information is provided for educational purposes and does not assure coverage of the specific item or service in each case. BioTissue and The Pinnacle Health Group make no guarantee of coverage or reimbursement of fees. These payment rates are nationally unadjusted average amounts and do not account for differences in payment due to geographic variation. Contact your local Medicare Administrative Contractor (MAC) or CMS for specific information as payment rates listed are subject to change. To the extent that you submit cost information to Medicare, Medicaid, or any other reimbursement program to support claims for services or items, you are obligated to accurately report the actual price paid for such items, including any subsequent adjustments. CPT® five-digit numeric codes, descriptions, and numeric modifiers only are Copyright AMA.

2024 BioTissue Ocular Coding Sheets – Prokera® & AmnioGraft®

Physician Fee Schedule – Facility and Non-Facility Settings (CY 2024)					
CPT	Descriptor	Medicare Physician Fee Schedule			
		NON-FACILITY		FACILITY	
		Non-Facility RVUs	National Average Payment	Facility RVUs	National Average Payment
Placement of Prokera					
65778	Placement of amniotic membrane on the ocular surface; without sutures	32.64	\$1,068.63	1.30	\$42.56
Placement of AmnioGraft					
65779	Placement of amniotic membrane on the ocular surface; single layer, sutured	34.67	\$1,135.10	3.49	\$114.26
Pterygium Procedural Coding					
65426	Excision or transposition of pterygium; <u>with graft</u>	20.00	\$654.80	14.24	\$466.22
Conjunctival Procedures					
65780	Ocular surface reconstruction; amniotic membrane transplantation, multiple layers	N/A	N/A	17.61	\$576.55
68110	Excision of lesion, conjunctiva; up to 1 cm	7.07	\$231.47	4.42	\$144.71
68115	Excision of lesion, conjunctiva; over 1 cm	9.93	\$325.11	5.44	\$178.11
68320	Conjunctivoplasty; with conjunctival graft or extensive rearrangement	22.21	\$727.16	16.07	\$526.13
68326	Conjunctivoplasty, reconstruction cul-de-sac; with conjunctival graft or extensive rearrangement	NA	N/A	19.14	\$626.64
68330	Repair of symblepharon; conjunctivoplasty, <u>without graft</u>	18.62	\$609.62	13.69	\$448.21
Glaucoma Procedures					
66170	Fistulization of sclera for glaucoma; trabeculectomy ab externo in absence of previous surgery	N/A	N/A	32.54	\$1,065.36
66172	Fistulization of sclera for glaucoma; trabeculectomy ab externo with scarring from previous ocular surgery or trauma (includes injection of antifibrotic agents)	N/A	N/A	35.54	\$1,163.58
66180	Aqueous shunt to extraocular equatorial plate reservoir, external approach; with graft	N/A	N/A	33.84	\$1,107.92
66185	Revision of aqueous shunt to extraocular equatorial plate reservoir; with graft	N/A	N/A	25.31	\$828.65
Supply Code					
V2790	Amniotic membrane for surgical reconstruction, per procedure	N/A	N/A	N/A	Contractor Priced



CPT 65426 / HCPCS V2790 Code Information:

CPT 65426: (Excision or transposition of pterygium; with graft) If the provider secures the amniotic membrane transplant with glue instead of using a conjunctival graft, CPT 65426 may still be reported. When reporting placement of the amniotic membrane separately, CPT 66999 should be reported if glue is used.

HCPCS V2790: V2790 – Amniotic membrane for surgical reconstruction, per procedure, is a supply code. Medicare and many Commercial payors consider payment for the supply included in the payment for the procedure code. Payors may have different policies regarding the supply of the amniotic tissue. Check your commercial payor policies and contracts to determine coverage and payment associated with CPT code 65778 and HCPCS code V2790, as this will vary from payor to payor.

HCPCS code V2790 should not be billed to Part B separately except as noted below:

- HCPCS code V2790 can be reimbursed separately in an office setting when billed with CPT Code 65780. A copy of the invoice must be submitted when billing V2790 and 65780 on the same claim.
- HCPCS code V2790 should not be billed with CPT Code 65775. However, if amniotic membrane application is required during that procedure, then either CPT Codes 65778 or 65779, depending on the method of application of the membrane must be billed with 65775 when a membrane is applied. As indicated above, CPT Codes 65778 and 65779 both include payment for the membrane itself (V2790) and therefore V2790 should not be billed separately when those codes are billed.

[CMS.gov](https://www.cms.gov)

References/Notes:

- The payment rates specified in this document are Centers for Medicare & Medicaid Services (CMS) national unadjusted averages. Actual payment rates will vary based on geographic adjustments and are updated quarterly. Commercial payment rates will vary per contract.
- By Report – For CPT codes that have not been assigned RVUs (e.g., miscellaneous codes), there is no national payment rate. Providers must provide detailed operative notes describing the service provided. If there is an existing service with an established CPT code that involves similar work, that CPT code may be provided as a suggested crosswalk for payment purposes.
- CY 2024 Changes to Hospital Outpatient Prospective Payment and Ambulatory Payment Systems – Final Rule with Comment and Final CY 2024 Payment Rates (CMS 1786-FC); Addendum B and ASC Addenda.
- CY 2024 Payment Policies under the Physician Fee Schedule and Other Changes to Part B Payment Policies; (CMS-1786-FC); Addendum B. All MPFS Fee Schedules calculated using CF of \$32.74 effective January 1, 2024.
- Current Procedural Terminology (CPT®) is a registered trademark of the American Medical Association.
- ICD-10-CM Expert for Physicians 2024, ©2023 Optum360, LLC. All rights reserved.

Key to Hospital Outpatient and ASC Settings Abbreviations:

SI – Status Indicator

APC – Ambulatory Payment Classifications

ASC – Ambulatory Surgical Center

OPPS – Hospital Outpatient Prospective Payment System

Q2 - Packaged APC payment if billed on the same claim as a HCPCS code assigned status indicator “T.” Otherwise, payment made through separate APC.

J1 - All covered Part B services on the claim are packaged with the primary “J1” service for the claim, except services with OPPS SI=F, G, H, L and U; ambulance services; diagnostic and screening mammography; all preventive services; and certain Part B inpatient services.

If two or more “J1” services appear on the same claim, the procedure with the higher rank based on cost is considered the “primary” service and payment is based upon the C-APC to which that service is assigned.

If you have any additional questions regarding coding, coverage and payment; or require assistance with pre-determination, prior authorization, or coverage appeals for a particular patient, please contact the BioTissue Reimbursement Hotline at **866-369-9290** or email biotissueocular@thepinnaclehealthgroup.com.

Procedure coding should be based upon medical necessity, procedures, and supplies provided to the patient. Coding and reimbursement information is provided for educational purposes only and does not assure coverage of the specific item or service in each case. BioTissue and The Pinnacle Health Group make no guarantee of coverage or reimbursement of fees. These payment rates are nationally unadjusted average amounts and do not account for differences in payment due to geographic variation. Contact your local Medicare Administrative Contractor (MAC) or CMS for specific information as payment rates listed are subject to change. To the extent that you submit cost information to Medicare, Medicaid, or any other reimbursement program to support claims for services or items, you are obligated to accurately report the actual price paid for such items, including any subsequent adjustments. CPT® five-digit numeric codes, descriptions, and numeric modifiers only are Copyright AMA.

In the Hospital Outpatient Prospective Payment System (OPPS), CMS assigns all CPT and HCPCS codes a Status Indicator (SI), which indicates when and how a service is considered for payment. Status indicators that apply to the procedures listed in this guide are provided below:

Facility Reimbursement – Hospital Outpatient and ASC Settings (CY 2024)					
CPT	Descriptor	OPPS			ASC
		SI	APC	Payment	Payment
Placement of Prokera®					
65778	Placement of amniotic membrane on the ocular surface; without sutures	Q2	5502	\$965.63	Packaged
Placement of AmnioGraft®					
65779	Placement of amniotic membrane on the ocular surface; single layer, sutured	Q2	5504	\$3,687.69	Packaged
Pterygium Procedures					
65426	Excision or transposition of pterygium; <u>with graft</u>	J1	5503	\$2, 228.8	\$978.55
Conjunctival Procedures					
65780	Ocular surface reconstruction; amniotic membrane transplantaion, multiple layers	J1	5504	\$3,687.69	\$1,487.34
68110	Excision of lesion, conjunctiva; up to 1 cm	J1	5503	\$2,228.80	\$167.32
68115	Excision of lesion, conjunctiva; over 1 cm	J1	5503	\$2,228.80	\$978.55
68320	Conjunctivoplasty; with conjunctival graft or extensive rearrangement	J1	5503	\$2,228.80	\$978.55
68326	Conjunctivoplasty, reconstruction cul-de-sac; with conjunctival graft or extensive rearrangement	J1	5504	\$3,687.69	\$1,487.34
68330	Repair of symblepharon; conjunctivoplasty, <u>without graft</u>	J1	5491	\$2,222.67	\$1,183.74
Glaucoma Procedures					
66170	Fistulization of sclera for glaucoma; trabeculectomy ab externo in absence of previous surgery	J1	5491	\$2,222.67	\$1,183.74
66172	Fistulization of sclera for glaucoma; trabeculectomy ab externo with scarring from previous ocular surgery or trauma (includes injection of antifibrotic agents)	J1	5491	\$2,222.67	\$1,183.74
66180	Aqueous shunt to extraocular equatorial plate reservoir, external approach; <u>with graft</u>	J1	5492	\$3,877.93	\$2,627.18
66185	Revision of aqueous shunt to extraocular equatorial plate reservoir; <u>with graft</u>	J1	5491	\$2,222.67	\$1,183.74
Supply Code					
V2790	Amniotic membrane for surgical reconstruction, per procedure	N	N/A	Packaged	Packaged

Procedure coding should be based upon medical necessity, procedures, and supplies provided to the patient. Coding and reimbursement information is provided for educational purposes only and does not assure coverage of the specific item or service in each case. BioTissue and The Pinnacle Health Group make no guarantee of coverage or reimbursement of fees. These payment rates are nationally unadjusted average amounts and do not account for differences in payment due to geographic variation. Contact your local Medicare Administrative Contractor (MAC) or CMS for specific information as payment rates listed are subject to change. To the extent that you submit cost information to Medicare, Medicaid, or any other reimbursement program to support claims for services or items, you are obligated to accurately report the actual price paid for such items, including any subsequent adjustments. CPT® five-digit numeric codes, descriptions, and numeric modifiers only are Copyright AMA.

The ICD-10 diagnostic codes listed below include only those that map to a CPT code relative to pterygium, conjunctival, or glaucoma procedure provided in the previous table. Codes ending with a “dash” mean additional digits may be required to obtain greater specificity.

Relevant Ocular Diagnosis Codes	
ICD-10-CM	Description
B94.0	Sequelae of trachoma
C69.0-	Malignant neoplasm
C79.49	Secondary malignant neoplasm of other parts of nervous system
D09.2-	Carcinoma in situ
D31.0-	Benign neoplasm of conjunctive
D48.7	Neoplasm of uncertain behavior of other specified sites
D49.89	Neoplasm of unspecified behavior of other specified sites
H04.12-	Dry eye syndrome of lacrimal glands
H10.81-	Pingueculitis
H11.00-	Unspecified pterygium
H11.01-	Amyloid pterygium
H11.02-	Central pterygium
H11.03-	Double pterygium
H11.04-	Peripheral pterygium
H11.05-	Peripheral pterygium, progressive
H11.44-	Conjunctival cysts
H11.06-	Recurrent pterygium
H11.21-	Conjunctival adhesions and strands (localized)
H11.22-	Conjunctival granuloma
H11.24-	Scarring of conjunctiva
H11.44-	Conjunctival cysts
H11.81-	Pseudopterygium of conjunctiva
H11.82-	Conjunctivochalasis
H16.00-	Unspecified corneal ulcer
H16.01-	Central corneal ulcer
H16.02-	Ring corneal ulcer
H16.03-	Corneal ulcer with hypopyon
H16.04-	Marginal corneal ulcer
H16.05-	Mooren's corneal ulcer
H16.06-	Mycotic corneal ulcer
H16.07-	Perforated corneal ulcer
H16.12-	Filamentary keratitis
H16.14-	Punctate keratitis
H16.223	Keratoconjunctivitis sicca, not specified as Sjogren's, bilateral
H16.23-	Neutrophic keratoconjunctivitis
H18.1-	Bullous keratopathy
H18.40	Unspecified corneal degeneration
H18.41-	Arcus senilis
H18.42-	Band keratopathy
H18.43	Other calcareous corneal degeneration
H18.44-	Keratomalacia

Procedure coding should be based upon medical necessity, procedures, and supplies provided to the patient. Coding and reimbursement information is provided for educational purposes only and does not assure coverage of the specific item or service in each case. BioTissue and The Pinnacle Health Group make no guarantee of coverage or reimbursement of fees. These payment rates are nationally unadjusted average amounts and do not account for differences in payment due to geographic variation. Contact your local Medicare Administrative Contractor (MAC) or CMS for specific information as payment rates listed are subject to change. To the extent that you submit cost information to Medicare, Medicaid, or any other reimbursement program to support claims for services or items, you are obligated to accurately report the actual price paid for such items, including any subsequent adjustments. CPT® five-digit numeric codes, descriptions, and numeric modifiers only are Copyright AMA.

Relevant Ocular Diagnosis Codes	
ICD-10-CM	Description
H18.45-	Nodular corneal degeneration
H18.46-	Peripheral corneal degeneration
H18.49	Other corneal degeneration
H18.50	Unspecified hereditary corneal dystrophies
H18.51	Endothelial corneal dystrophy
H18.52	Epithelial (juvenile) corneal dystrophy
H18.53	Granular corneal dystrophy
H18.54	Lattice corneal dystrophy
H18.55	Macular corneal dystrophy
H18.59	Other hereditary corneal dystrophies
H18.73-	Descemetocoele
H18.82-	Corneal disorder due to contact lens
H40.05-	Ocular hypertension
H40.06-	Primary angle closure without glaucoma damage
H40.10X-	Unspecified open-angle glaucoma
H40.11-	Primary open-angle glaucoma
H40.12-	Low-tension glaucoma
H40.13-	Pigmentary glaucoma
H40.14-	Capsular glaucoma with pseudoexfoliation of lens
H40.15-	Residual stage of open-angle glaucoma
H40.20X-	Unspecified primary angle-closure glaucoma
H40.22-	Chronic angle-closure glaucoma
H40.23-	Intermittent angle-closure glaucoma
H40.24-	Residual stage of angle-closure glaucoma
H40.30-	Glaucoma secondary to eye trauma
H40.40-	Glaucoma secondary to eye inflammation
H40.50-	Glaucoma secondary to other eye disorders
H40.60-	Glaucoma secondary to drugs
H40.81-	Glaucoma with increased episcleral venous pressure
H40.82-	Hypersecretion glaucoma
H40.83-	Aqueous misdirection
H40.89	Other specified glaucoma
H40.9	Unspecified glaucoma
H42	Glaucoma in diseases classified elsewhere
H59.09-	Other disorders of the eye following cataract surgery
L51.1	Stevens-Johnson syndrome
Q13.1	Absence of iris
Q15.0	Congenital glaucoma
S05.0-	Injury of conjunctiva and corneal abrasion without foreign body
T26.1-	Burn of cornea
T26.6-	Corrosion of cornea and conjunctival sac
T26.7	Corrosion with resulting rupture and destruction of eyeball
T26.8	Corrosions of other specified parts of eye and adnexa
T26.9	Corrosion of eye and adnexa, part unspecified
T86.84-	Corneal transplant

If you have any additional questions regarding coding, coverage and payment; or require assistance with pre-determination, prior authorization, or coverage appeals for a particular patient, please contact the BioTissue Reimbursement Hotline at 866-369-9290 or email biotissueocular@thepinnaclehealthgroup.com.

Procedure coding should be based upon medical necessity, procedures, and supplies provided to the patient. Coding and reimbursement information is provided for educational purposes only and does not assure coverage of the specific item or service in each case. BioTissue and The Pinnacle Health Group make no guarantee of coverage or reimbursement of fees. These payment rates are nationally unadjusted average amounts and do not account for differences in payment due to geographic variation. Contact your local Medicare Administrative Contractor (MAC) or CMS for specific information as payment rates listed are subject to change. To the extent that you submit cost information to Medicare, Medicaid, or any other reimbursement program to support claims for services or items, you are obligated to accurately report the actual price paid for such items, including any subsequent adjustments. CPT® five-digit numeric codes, descriptions, and numeric modifiers only are Copyright AMA.

Common Modifiers Used in Ophthalmology Billing

RT* – Right eye

LT* – Left eye

E1 – Upper left eyelid

E2 – Lower left eyelid

E3 – Upper right eyelid

E4 – Lower right eyelid

24 – Use for unrelated E/M by the same doctor during the postoperative period.

25 – Used when a distinct service is provided by the same doctor on the same day as another procedure. Appended to E/M code, not surgical code.

50* – Bilateral procedure

51 – Use when multiple procedures are performed on the same day during the same encounter.

57 – Appended to an exam when the decision to perform a major surgery was made at this encounter.

58 – Staged procedure

59 – Used when two different procedures that are not normally reported together are appropriately billed together under the set circumstances.

78 - Unplanned Return to the Operating/Procedure Room by the Same Physician or Other Qualified Health Care Professional Following Initial Procedure for a Related Procedure During the Postoperative Period.

79 – Use for unrelated procedure during the postoperative period performed by the same doctor.

*Not all ICD-10 diagnosis codes include laterality, but when a code does, ensure that the diagnosis code and appended modifier are telling the same story.

Proper Documentation

Medical records should be complete, legible, and include the following information:

- Appropriate ICD-10 Diagnosis
- Diagnosis-related patient history
- All tried and failed therapies (including duration) AND results observed
- Results from relevant diagnostic testing and exam findings (examples):
 - Ocular Surface Damage (e.g., staining)
 - Sensitivity Test results
 - MMP-9 or Osmolarity Test Results
- Rationale/Justification for the use of Prokera
- Results expected from Prokera treatment
- Document Amniotic Membrane used was **Prokera (or AmnioGraft if applicable)**.
 - Payors recognize Prokera & AmnioGraft and created their policies originally for these products.
 - Allows physicians to leverage the 30+ years of continuous research and published clinical results.

Documentation Requirements for Medicare Services

Source: [cms.gov](https://www.cms.gov)

1. All documentation must be maintained in the patient's medical record and made available to the contractor upon request.
2. Every page of the record must be legible and include appropriate patient identification information (e.g., complete name, dates of service[s]). The documentation must include the legible signature of the physician or non-physician practitioner responsible for and providing the care to the patient.
3. The submitted medical record must support the use of the selected ICD-10-CM code(s). The submitted CPT/HCPCS code must describe the service performed.

Sample CMS-1500 Claim form NOTE: Dates must be in 6- or 8-digit format. (MM/DD/YY or MM/DD/CCYY)

HEALTH INSURANCE CLAIM FORM

APPROVED BY NATIONAL UNIFORM CLAIM COMMITTEE (NUCC) 02-01-2019

Box 1: Select payor.

Boxes 2-7: Patient and Guarantor's information.

Boxes 9- 9d: Patient other insurance info (if applicable) 9b, 9c leave blank.

Box 10: Answer questions regarding injury, or accident. Completion of 10a-c is required.

Boxes 14 & 15: Insert dates if the visit is related to current illness or injury.

Box 17: If there is a referring provider, insert their name here. If no referring provider, doctor seeing patient that day goes here. Box 17b: NPI of MD listed in Box 17.

Box 19: List Amniotic Membrane product by name here.

Box 21: List Diagnosis codes here. See additional note below.

Box 24A, B, C, etc.: CPT/HCPCS codes, dates of service, diagnoses pointers, charges, units, etc. See additional note below.

Box 21D: IMPORTANT INFO Regarding diagnosis code sequence: If you include multiple diagnosis codes on a single claim, place them in order according to significance. (The first-listed (i.e., primary) code being the one that most strongly supports the medical necessity of your services.)

Box 24D: IMPORTANT INFO Regarding CPT code sequence: Sequencing CPT Codes is crucial to appropriate claims submission and appropriate reimbursement. When reporting claims with multiple CPT codes, sequence the codes from highest to lowest relative value.

Box 24D, cont.: IMPORTANT INFO Regarding modifier sequence: The general order of sequencing modifiers is (1) pricing (2) payment (3) location. Location modifiers, in all coding situations, are coded "last".

Four Line Insurance address:
 1st Line – Name
 2nd Line – First line of address
 3rd Line – Second line of address, if necessary
 4th Line – City, State (2 characters) and ZIP code

Note: Do not use punctuation (i.e., commas, periods) or other symbols in the address. Enter 9-digit ZIP codes

Box 1a: Patient insurance

Box 8: Leave blank.

Box 11: Patient ins. GROUP#

Box 11c: Insert insurance name.

Box 16: If it's a work-related injury (workers comp) info goes here. If not, leave blank.

Box 22: If you are submitting a void/replacement paper CMS 1500 claim, complete box 22.
 When resubmitting a claim, enter the appropriate bill frequency code left justified in the left-hand side of the field.
 7 = Replacement of prior claim
 8 = Void/cancel of prior claim
 Enter original claim reference number in right side of field.

Box 21D: IMPORTANT INFO Regarding diagnosis code sequence: If you include multiple diagnosis codes on a single claim, place them in order according to significance. (The first-listed (i.e., primary) code being the one that most strongly supports the medical necessity of your services.)

Box 24D: IMPORTANT INFO Regarding CPT code sequence: Sequencing CPT Codes is crucial to appropriate claims submission and appropriate reimbursement. When reporting claims with multiple CPT codes, sequence the codes from highest to lowest relative value.

Box 24D, cont.: IMPORTANT INFO Regarding modifier sequence: The general order of sequencing modifiers is (1) pricing (2) payment (3) location. Location modifiers, in all coding situations, are coded "last".

Service Request Form for BioTissue Product: ☐ Prokera ☐ AmnioGraft

Reason For Request: ☐ Prior Auth (PA) ☐ Pre-Determination (PD) ☐ PA/PD Appeal ☐ Claim Denial / Appeal

Provider Information

PROCEDURE DATE:

Place of Service:

☐ Physician Office ☐ Ambulatory Surgical Center ☐ Hospital Inpatient ☐ Hospital Outpatient ☐ Other (Specify)

Rendering Physician Name:

NPI:

TIN:

Medicare PTAN:

Address:

Provider Phone:

Provider Fax:

City/State:

Contact Person:

Contact Phone:

Contact Email Address:

Contact Fax:

Facility Information

Facility Name:

Facility Phone:

Facility Fax:

Facility Address:

Facility TIN:

Facility NPI:

Patient Information

Patient Name:

Address:

City:

State:

Zip code:

Gender:

DOB:

Home Phone:

Cell Phone:

Primary Ins:

Ins ID#

Group#

Ins. Phone:

Subscriber Name:

Subscriber DOB:

Secondary Ins:

Ins ID#

Group#

Ins. Phone:

Subscriber Name:

Subscriber DOB:

Procedure information

Diagnosis:

ICD-10 Code(s):

CPT/HCPCS Code(s):

Patient Consent

Patient Consent signed and on file (Y/N)

Date signed

Please include all supporting clinical documentation such as treatment plan, progress notes, and LOMN.

The Pinnacle Health Group cannot guarantee coverage or reimbursement for any product or procedure, nor is benefit verification a guarantee of coverage for services rendered. Third-party payment for medical products and services is affected by numerous factors. It is always the provider's responsibility to determine and submit appropriate codes, charges and modifiers for services rendered.

Published Clinical Evidence

This information can be used with any Letter of Medical Necessity, Appeal, Prior Authorization request, etc.

Punctate Keratitis (PK):

- ¹ Morkin MI and Hamrah P. Efficacy of self- retained cryopreserved amniotic membrane for treatment of neuropathic corneal pain. *The Ocular Surface*. 2018; 16: 132-8[76].
- ² Tighe S. (2018) Use of Amniotic Membrane in Corneal Ulcers with or without Neurotrophic Keratitis. 2018 ASCRS/ASOA Symposium and Congress. Paper [149].
- ³ Brocks D, Mead OG, Tighe S, Tseng SC. Self-Retained Cryopreserved Amniotic Membrane for the Management of Corneal Ulcers. *Clinical Ophthalmology*. 2020 May 26; 14:1437-43 [146].
- ⁴ Yin HY, Cheng AM, Tighe S, Kurochkin P, Nord J, Dhanireddy S, Swan R, Alpert S. Self-retained cryopreserved amniotic membrane for treating severe corneal ulcers: a comparative, retrospective control study. *Scientific Reports*. 2020 Oct 12;10(1):1-5[145].
- ⁵ Yeu E, Tighe S, Sheha H. Optimizing ocular surface prior to Cataract Surgery. 2017 AAO, New Orleans, LA.
- ⁶ Sheha H, Tighe S. (2018) Self-Retained Amniotic Membrane for Epithelial Basement Membrane Dystrophy. 2018 ASCRS/ASOA Symposium and Congress. Poster[150].
- ⁷ Cheng AMS and Tseng SCG. Self-Retained Amniotic Membrane Combined with Antiviral Therapy for Herpetic Epithelial Keratitis. *Cornea*. 2017; 36: 1383-6[161].
- ⁸ Doll T. Cryopreserved Amniotic Membrane, Autologous Serum Eye Drops, and Tea-Tree Oil Lid Scrubs in combination for the treatment of Keratoconjunctivitis in a Staphylococcus Hypersensitive Teenager. *Journal of Dry Eye Disease*. 2017; 1: e1-e10.[162]
- ⁹ Sheha H, Tighe S, Cheng AMS and Tseng SCG. A stepping-stone in treating dendritic keratitis. *American Journal of Ophthalmology Case Reports*. 2017; 7: 55-8[163].
- ¹⁰ Harthan J and A Sicks L. Sutureless Amniotic Membranes (Prokera) for Filamentary Keratitis: A Case Series. *Journal of Dry Eye and Ocular Surface Disease*. 2019; 2: e10-e6[164].
- ¹¹ Cheng AMS, Tighe S, Sheha H and Tseng SCG. Adjunctive role of self-retained cryopreserved amniotic membrane in treating immune-related dry eye disease. *International Ophthalmology*. 2018; 38: 2219-22[122].
- ¹² McDonald M, Janik SB, Bowden FW, Chokshi A, Singer MA, Tighe S, Mead OG, Nanda S, Qazi MA, Dierker D, Shupe AT, McMurren BJ. Association of Treatment Duration and Clinical Outcomes in Dry Eye Treatment with Sutureless Cryopreserved Amniotic Membrane. *Clin Ophthalmol*. 2023;17:2697-2703.
- ¹³ John T, Tighe S, Sheha H, et al. Corneal Nerve Regeneration after Self-Retained Cryopreserved Amniotic Membrane in Dry Eye Disease. *J Ophthalmology* 2017; Volume 2017, Article ID 6404918, 10 pages. <https://doi.org/10.1155/2017/6404918>

Neurotrophic Keratitis (NK):

- ¹ Morkin MI and Hamrah P. Efficacy of self- retained cryopreserved amniotic membrane for treatment of neuropathic corneal pain. *The Ocular Surface*. 2018; 16: 132-8[76].
- ² Tighe S. (2018) Use of Amniotic Membrane in Corneal Ulcers with or without Neurotrophic Keratitis. 2018 ASCRS/ASOA Symposium and Congress. Paper[149].
- ³ Brocks D, Mead OG, Tighe S, Tseng SC. Self-Retained Cryopreserved Amniotic Membrane for the Management of Corneal Ulcers. *Clinical Ophthalmology*. 2020 May 26; 14:1437-43[146].
- ⁴ Yin HY, Cheng AM, Tighe S, Kurochkin P, Nord J, Dhanireddy S, Swan R, Alpert S. Self-retained cryopreserved amniotic membrane for treating severe corneal ulcers: a comparative, retrospective control study. *Scientific Reports*. 2020 Oct 12;10(1):1-5[145].
- ⁵ Yeu E, Tighe S, Sheha H. Optimizing ocular surface prior to Cataract Surgery. 2017 AAO, New Orleans, LA.
- ⁶ Sheha H, Tighe S. (2018) Self-Retained Amniotic Membrane for Epithelial Basement Membrane Dystrophy. 2018 ASCRS/ASOA Symposium and Congress. Poster[150].
- ⁷ Cheng AMS and Tseng SCG. Self-Retained Amniotic Membrane Combined with Antiviral Therapy for Herpetic Epithelial Keratitis. *Cornea*. 2017; 36: 1383-6[161].
- ⁸ Doll T. Cryopreserved Amniotic Membrane, Autologous Serum Eye Drops, and Tea-Tree Oil Lid Scrubs in combination for the treatment of Keratoconjunctivitis in a Staphylococcus Hypersensitive Teenager. *Journal of Dry Eye Disease*. 2017; 1: e1-e10 [162].
- ⁹ Sheha H, Tighe S, Cheng AMS and Tseng SCG. A stepping-stone in treating dendritic keratitis. *American Journal of Ophthalmology Case Reports*. 2017; 7: 55-8 [163].
- ¹⁰ Harthan J and A Sicks L. Sutureless Amniotic Membranes (Prokera) for Filamentary Keratitis: A Case Series. *Journal of Dry Eye and Ocular Surface Disease*. 2019; 2: e10-e6 [164].
- ¹¹ John T, Tighe S, Sheha H, et al. Corneal Nerve Regeneration after Self- Retained Cryopreserved Amniotic Membrane in Dry Eye Disease. *Journal of Ophthalmology*. 2017; 2017: 6404918[75].

Recurrent Corneal Erosion (RCE):

- ¹ Huang YS, H; Tseng S.G. Self-retained Amniotic Membrane Transplantation for Recurrent Corneal Erosion. *Journal of Clinical and Experimental Ophthalmology*. 2013; 4:272[155].
- ² Desai NR. A comparison of cryopreserved amniotic membrane and bandage contact lens in their ability to provide high- quality healing after superficial keratectomy. *Review of Ophthalmology*. 2014[152].
- ³ Morkin MI and Hamrah P. Efficacy of self- retained cryopreserved amniotic membrane for treatment of neuropathic corneal pain. *The Ocular Surface*. 2018; 16: 132-8[76].
- ⁴ Tighe S. (2018) Use of Amniotic Membrane in Corneal Ulcers with or without Neurotrophic Keratitis. *2018 ASCRS/ASOA Symposium and Congress*. Paper[149].
- ⁵ Brocks D, Mead OG, Tighe S, Tseng SC. Self-Retained Cryopreserved Amniotic Membrane for the Management of Corneal Ulcers. *Clinical Ophthalmology*. 2020 May 26; 14:1437-43[146].
- ⁶ Yin HY, Cheng AM, Tighe S, Kurochkin P, Nord J, Dhanireddy S, Swan R, Alpert S. Self-retained cryopreserved amniotic membrane for treating severe corneal ulcers: a comparative, retrospective control study. *Scientific Reports*. 2020 Oct 12;10(1):1-5[145].
- ⁷ Yeu E, Tighe S, Sheha H. Optimizing ocular surface prior to Cataract Surgery. 2017 AAO, New Orleans, LA.
- ⁸ Sheha H, Tighe S. (2018) Self-Retained Amniotic Membrane for Epithelial Basement Membrane Dystrophy. *2018 ASCRS/ASOA Symposium and Congress*. Poster[150].
- ⁹ Cheng AMS and Tseng SCG. Self-Retained Amniotic Membrane Combined with Antiviral Therapy for Herpetic Epithelial Keratitis. *Cornea*. 2017; 36: 1383-6[161].
- ¹⁰ Doll T. Cryopreserved Amniotic Membrane, Autologous Serum Eye Drops, and Tea-Tree Oil Lid Scrubs in combination for the treatment of Keratoconjunctivitis in a Staphylococcus Hypersensitive Teenager. *Journal of Dry Eye Disease*. 2017; 1: e1-e10[162].
- ¹¹ Sheha H, Tighe S, Cheng AMS and Tseng SCG. A stepping-stone in treating dendritic keratitis. *American Journal of Ophthalmology Case Reports*. 2017; 7: 55-8[163].
- ¹² Harthan J and A Sicks L. Sutureless Amniotic Membranes (Prokera) for Filamentary Keratitis: A Case Series. *Journal of Dry Eye and Ocular Surface Disease*. 2019; 2: e10-e6[164].

Corneal Ulcers:

- ¹ Barrett RT, Hastings JP, Ronquillo YC, Hoopes PC, Moshirfar M. Coral Keratitis: Case Report and Review of Mechanisms of Action, Clinical Management and Prognosis of Ocular Exposure to Palytoxin. *Clinical Ophthalmology (Auckland, NZ)*. 2021;15:141.
- ² Ahuja AS, Bowden FW 3rd, Robben JL. A Novel Treatment for Neurotrophic Corneal Ulcer Using Topical Cenegermin (OXERVATE™) Containing Recombinant Human Nerve Growth Factor. *Cureus*. 2020 Nov 27;12(11):e11724.
- ³ Yin HY, Cheng AM, Tighe S, Kurochkin P, Nord J, Dhanireddy S, Swan R, Alpert S. Self-retained cryopreserved amniotic membrane for treating severe corneal ulcers: a comparative, retrospective control study. *Scientific Reports*. 2020 Oct 12;10(1):1-5.
- ⁴ Trinh T, Santaella G, Mimouni M, Mednick Z, Cohen E, Sorkin N, Rootman DS, Slomovic AR, Chan CC. Assessment of response to multimodal management of neurotrophic corneal disease. *The Ocular Surface*. 2020 Nov 12.
- ⁵ Sohal RJ, Aung TT, Sohal S, Harish A. A Rare Cause of Bilateral Corneal Ulcers: Vitamin A Deficiency in the Setting of Chronic Alcoholism. *Cureus*. 2020 May;12(5).
- ⁶ Brocks D, Mead OG, Tighe S, Tseng SC. Self-Retained Cryopreserved Amniotic Membrane for the Management of Corneal Ulcers. *Clinical Ophthalmology*. 2020 May 26;14:1437-43.
- ⁷ Brocks D, Sheha H, Tighe S. (2018) Use of Amniotic Membrane in Corneal Ulcers with or without Neurotrophic Keratitis. *2018 ASCRS/ASOA Symposium and Congress paper*.
- ⁸ Morkin MI and Hamrah P. Efficacy of self- retained cryopreserved amniotic membrane for treatment of neuropathic corneal pain. *The Ocular Surface*. 2018; 16: 132-8.
- ⁹ Heur M and Yiu S. Repair of Spontaneous Corneal Perforation in Pellucid Marginal Degeneration Using Amniotic Membrane. *Open Journal of Ophthalmology*. 2015; 05: 163-6.
- ¹⁰ Kassm T and Ursea R. The value of amniotic membrane patch in the treatment of corneal thinning as assessed by anterior segment optical coherence tomography. *Investigative Ophthalmology & Visual Science*. 2014; 55: 2466.
- ¹¹ Emily A. McCourt, Leslie A. Wei, Shawn Richards, Michael J. Taravella, Robert W. Enzenauer; A Novel Use of Amniotic Membrane for The Treatment of Bilateral Corneal Ulcers Due to Severe Vitamin A Deficiency in An Autistic Child. *Investigative Ophthalmology & Visual Science*. 2012;53(14):1870.

Corneal Dystrophies:

- ¹ Sheha H, Tighe S. Self-Retained Amniotic Membrane for Epithelial Basement Membrane Dystrophy. 2018 ASCRS/ASOA Symposium and Congress. Poster. 2018.
- ² Sheha H. Self-Retained Amniotic Membrane after Debridement for Epithelial Basement Membrane Dystrophy. *Insights in Ophthalmology*. 2018;4.
- ³ Yeu E, Hashem O, Sheha H. Treatment of Epithelial Basement Membrane Dystrophy to Optimize the Ocular Surface Prior to Cataract Surgery. *Clinical Ophthalmology* (Auckland, NZ). 2022;16:785.
- ⁴ Desai NR. A comparison of cryopreserved amniotic membrane and bandage contact lens in their ability to provide high- quality healing after superficial keratectomy. *Review of Ophthalmology*. 2014.
- ⁵ Huang YS, H; Tseng S.G. Self-retained Amniotic Membrane Transplantation for Recurrent Corneal Erosion. *Journal of Clinical and Experimental Ophthalmology*. 2013;4:272.
- ⁶ Hauswirth S, Hom M. Cryopreserved Amniotic Membrane After Epithelial Debridement for Recurrent Corneal Erosion. *Invest. Ophthalmol. Vis. Sci*. 2016;57(12):4356
- ⁷ Hauswirth S, Hom M. Taking the Recurrence out of Recurrent Corneal Erosions: A Case Series. *Invest. Ophthalmol. Vis. Sci*. 2017;58(8):2612.
- ⁸ Hauswirth. The Effect of Debridement and Amnion Tissue on Vision in Patients with Anterior Basement Membrane Dystrophy: A Short Case Series. *Invest. Ophthalmol. Vis. Sci*. 2015; 56(7):5641.
- ⁹ Sheha H, Tighe S, Cheng AM and Tseng SC. Amniotic Membrane Transplantation. *Expert Techniques in Ophthalmic Surgery*. 2015, p. 167-75.
- ¹⁰ Sheppard J, Yeu E and Tseng S. Sutureless Cryopreserved Amniotic Membrane Transplantation Accelerates Ocular Surface Healing and Topographic Stabilization for Dry Eye Patients. 2015; 355-6.

Persistent Epithelial Defect (PED):

- ¹ Cheng AM, Zhao D, Chen R, et al. Accelerated restoration of ocular surface health in dry eye disease by self-retained cryopreserved amniotic membrane. *Ocul Surf*. 2016;14(1):56-63.
- ² Yin HY, Cheng AM, Tighe S, Kurochkin P, Nord J, Dhanireddy S, Swan R, Alpert S. Self-retained cryopreserved amniotic membrane for treating severe corneal ulcers: a comparative, retrospective control study. *Scientific Reports*. 2020 Oct 12;10(1):1-5[145].
- ³ Brocks D, Mead OG, Tighe S, Tseng SC. Self-Retained Cryopreserved Amniotic Membrane for the Management of Corneal Ulcers. *Clinical Ophthalmology*. 2020 May 26; 14:1437-43[146].
- ⁴ Morkin MI and Hamrah P. Efficacy of self- retained cryopreserved amniotic membrane for treatment of neuropathic corneal pain. *The Ocular Surface*. 2018; 16: 132-8[76].
- ⁵ Tighe S. (2018) Use of Amniotic Membrane in Corneal Ulcers with or without Neurotrophic Keratitis. 2018 ASCRS/ASOA Symposium and Congress. Paper[149].
- ⁶ Brocks D, Mead OG, Tighe S, Tseng SC. Self-Retained Cryopreserved Amniotic Membrane for the Management of Corneal Ulcers. *Clinical Ophthalmology*. 2020 May 26; 14:1437-43[146].
- ⁷ Yin HY, Cheng AM, Tighe S, Kurochkin P, Nord J, Dhanireddy S, Swan R, Alpert S. Self-retained cryopreserved amniotic membrane for treating severe corneal ulcers: a comparative, retrospective control study. *Scientific Reports*. 2020 Oct 12;10(1):1-5[145].
- ⁸ Yeu E, Tighe S, Sheha H. Optimizing ocular surface prior to Cataract Surgery. 2017 AAO, New Orleans, LA.
- ⁹ Sheha H, Tighe S. (2018) Self-Retained Amniotic Membrane for Epithelial Basement Membrane Dystrophy. 2018 ASCRS/ASOA Symposium and Congress. Poster.[150].
- ¹⁰ Cheng AMS and Tseng SCG. Self-Retained Amniotic Membrane Combined with Antiviral Therapy for Herpetic Epithelial Keratitis. *Cornea*. 2017; 36: 1383-6[161].
- ¹¹ Doll T. Cryopreserved Amniotic Membrane, Autologous Serum Eye Drops, and Tea-Tree Oil Lid Scrubs in combination for the treatment of Keratoconjunctivitis in a Staphylococcus Hypersensitive Teenager. *Journal of Dry Eye Disease*. 2017; 1: e1-e10[162].
- ¹² Sheha H, Tighe S, Cheng AMS and Tseng SCG. A stepping-stone in treating dendritic keratitis. *American Journal of Ophthalmology Case Reports*. 2017; 7: 55-8[163].
- ¹³ Harthan J and A Sicks L. Sutureless Amniotic Membranes (Prokera) for Filamentary Keratitis: A Case Series. *Journal of Dry Eye and Ocular Surface Disease*. 2019; 2: e10-e6[164].
- ¹³ Lam SS, Sklar BA, Schoen M, Rapuano CJ. Severe ocular alkali injury managed with an externally sutured amniotic membrane and customized symblepharon ring. *Taiwan J Ophthalmol*. 2022 Dec 2;13(1):101-105. doi: 10.4103/2211-5056.362597. PMID: 37252174; PMCID: PMC10220433.

Severe Dry Eye:

- ¹ Cheng AM, Zhao D, Chen R, et al. Accelerated restoration of ocular surface health in dry eye disease by self-retained cryopreserved amniotic membrane. *Ocul Surf.* 2016;14(1):56-63.
- ² Cheng AM, Zhao D, Chen R, et al. Accelerated Restoration of Ocular Surface Health in Dry Eye Disease by Self- Retained Cryopreserved Amniotic Membrane. *The Ocular Surface.* 2016; 14: 56-63[121]
- ³ John T, Tighe S, Sheha H, et al. Corneal Nerve Regeneration after Self- Retained Cryopreserved Amniotic Membrane in Dry Eye Disease. *Journal of Ophthalmology.* 2017; 2017: 6404918[75]
- ⁴ McDonald MB, Sheha H, Tighe S, et al. Treatment outcomes in the Dry Eye Amniotic Membrane (DREAM) study. *Journal of Clinical Ophthalmology* (Auckland, NZ). 2018; 12: 677-81[119]
- ⁵ Morkin MI and Hamrah P. Efficacy of self- retained cryopreserved amniotic membrane for treatment of neuropathic corneal pain. *The Ocular Surface.* 2018; 16: 132-8[76]
- ⁶ Tighe S. (2018) Use of Amniotic Membrane in Corneal Ulcers with or without Neurotrophic Keratitis. *2018 ASCRS/ASOA Symposium and Congress. Paper.*[149]
- ⁷ Brocks D, Mead OG, Tighe S, Tseng SC. Self-Retained Cryopreserved Amniotic Membrane for the Management of Corneal Ulcers. *Clinical Ophthalmology.* 2020 May 26; 14:1437-43.[146]
- ⁸ Yin HY, Cheng AM, Tighe S, Kurochkin P, Nord J, Dhanireddy S, Swan R, Alpert S. Self-retained cryopreserved amniotic membrane for treating severe corneal ulcers: a comparative, retrospective control study. *Scientific Reports.* 2020 Oct 12;10(1):1-5.[145]
- ⁹ Yeu E, Tighe S, Sheha H. Optimizing ocular surface prior to Cataract Surgery. *2017 AAO, New Orleans, LA.*
- ¹⁰ Sheha H, Tighe S. (2018) Self-Retained Amniotic Membrane for Epithelial Basement Membrane Dystrophy. *2018 ASCRS/ASOA Symposium and Congress. Poster*[150].
- ¹¹ Cheng AMS and Tseng SCG. Self-Retained Amniotic Membrane Combined with Antiviral Therapy for Herpetic Epithelial Keratitis. *Cornea.* 2017; 36: 1383-6[161].
- ¹² Doll T. Cryopreserved Amniotic Membrane, Autologous Serum Eye Drops, and Tea-Tree Oil Lid Scrubs in combination for the treatment of Keratoconjunctivitis in a Staphylococcus Hypersensitive Teenager. *Journal of Dry Eye Disease.* 2017; 1: e1-e10[162].
- ¹³ Sheha H, Tighe S, Cheng AMS and Tseng SCG. A stepping-stone in treating dendritic keratitis. *American Journal of Ophthalmology Case Reports.* 2017; 7: 55-8[163].
- ¹⁴ Harthan J and A Sicks L. Sutureless Amniotic Membranes (Prokera) for Filamentary Keratitis: A Case Series. *Journal of Dry Eye and Ocular Surface Disease.* 2019; 2: e10-e6[164].
- ¹⁵ McDonald M, Janik SB, Bowden FW, Chokshi A, Singer MA, Tighe S, Mead OG, Nanda S, Qazi MA, Dierker D, Shupe AT, McMurren BJ. Association of Treatment Duration and Clinical Outcomes in Dry Eye Treatment with Sutureless Cryopreserved Amniotic Membrane. *Clin Ophthalmol.* 2023;17:2697-2703.

Corneal Abrasion

- ¹ Baldwin HC, Marshall J. Growth factors in corneal wound healing following refractive surgery: a review. *Acta Ophthalmologica Scandinavica.* 2002;80(3):238-247.
- ² Vlasov A, Sia RK, Ryan DS, et al. Sutureless cryopreserved amniotic membrane graft and wound healing after photorefractive keratectomy. *Journal of Cataract & Refractive Surgery.* 2016;42(3):435-443.
- ³ Vlasov A, Sia RK, Ryan DS, et al. Sutureless cryopreserved amniotic membrane graft and wound healing after photorefractive keratectomy. *Journal of Cataract & Refractive Surgery.* 2016;42(3):435-443.
- ⁴ Suri K, Kosker M, Raber IM, et al. Sutureless amniotic membrane ProKera for ocular surface disorders: short-term results. *Eye & contact lens.* 2013;39(5):341-347.
- ⁵ Pachigolla G, Prasher P, Di Pascuale MA, McCulley JP, McHenry JG, Mootha VV. Evaluation of the role of ProKera in the management of ocular surface and orbital disorders. *Eye & contact lens.* 2009;35(4):172-175.
- ⁶ Shanbhag SS, Hall L, Chodosh J, Saeed HN. Long-term outcomes of amniotic membrane treatment in acute Stevens- Johnson syndrome/toxic epidermal necrolysis. *The ocular surface.* 2020;18(3):517-522.
- ⁷ John T, Tighe S, Sheha H, et al. Corneal nerve regeneration after self-retained cryopreserved amniotic membrane in dry eye disease. *Journal of ophthalmology.* 2017;2017.
- ⁸ Cox AR, Sia RK, Purt B, et al. Assessment of corneal haze after PRK and the effect of sutureless amniotic membrane graft by corneal densitometry. *Journal of Refractive Surgery.* 2020;36(5):293-299.
- ⁹ Al-Kharashi S, Al-Khawaja A, Gonnah E-S, et al. Microbial keratitis after amniotic membrane transplantation. *International ophthalmology.* 2005;26(3):73-76.
- ¹⁰ Turkoglu E, Celik E, Alagoz G. A comparison of the efficacy of autologous serum eye drops with amniotic membrane transplantation in neurotrophic keratitis. *Paper presented at: Seminars in ophthalmology 2014.*

EBMD/ABMD:

- ¹ Sheha H, Tighe S. Self-Retained Amniotic Membrane for Epithelial Basement Membrane Dystrophy. *2018 ASCRS/ASOA Symposium and Congress*. Poster. 2018.
- ² Sheha H. Self-Retained Amniotic Membrane after Debridement for Epithelial Basement Membrane Dystrophy. *Insights in Ophthalmology*. 2018;4.
- ³ Yeu E, Hashem O, Sheha H. Treatment of Epithelial Basement Membrane Dystrophy to Optimize the Ocular Surface Prior to Cataract Surgery. *Clinical Ophthalmology* (Auckland, NZ). 2022;16:785.
- ⁴ Hauswirth. The Effect of Debridement and Amnion Tissue on Vision in Patients with Anterior Basement Membrane Dystrophy: A Short Case Series. *Invest. Ophthalmol. Vis. Sci*. 2015; 56(7):5641.
- ⁵ Sheppard J, Yeu E and Tseng S. Sutureless Cryopreserved Amniotic Membrane Transplantation Accelerates Ocular Surface Healing and Topographic Stabilization for Dry Eye Patients. *13th International Symposium on Sjögren's Syndrome*. 2015; 355-6.

Studies for other conditions:

Please contact BioTissue Medical Affairs to obtain additional studies related to other conditions. Medical Affairs can be reached at this email: MedicalAffairs@tbiotissue.com.

Sample Prior Authorization Request Letter

Diagnosis: Punctate Keratitis

Please include physician letterhead on Prior Authorization Letters

[Date]

[Payor Contact]

[Title]

[Address]

[City, State, Zip]

Re: [Patient Name]

[Patient Identification Number]

[Date of Service]

Dear [Payor Contact]:

I am writing on behalf of my patient, [patient's name], to request prior authorization for the use of Prokera® for the treatment of their Punctate Keratitis (PK). To date, [include tried therapies] have been tried in an attempt to resolve [patient's name] condition, but all have failed. My patient's eye condition is deteriorating, and they are at risk of further corneal ulceration or perforation. As such, I believe Prokera is a medically necessary next logical step in their treatment protocol, to provide them relief from the symptoms associated with this disease, heal their cornea, and restore their quality of life.

Patient History

[Patient History, including additional rationale as to why this is the preferred treatment option to treat the condition of this patient (i.e., patient is not a surgical candidate). Physician may also want to expand upon his/her experience with prior use of Prokera.]

Prokera is a corneal bandage containing a piece of Cryopreserved Amniotic Membrane (CAM) graft fastened into fastened into an ophthalmic conformer ring system. The ring sits on the ocular surface like a symblepharon ring, and the stromal side of the CAM is in contact with the corneal surface and limbal area. The Prokera CAM provides natural therapeutic biologic actions that include reduction in scarring, blood vessel formation, and inflammation, while promoting the healing of the ocular surface. The conformer ring also helps maintain space in the orbital cavity and to prevent conjunctival closure or adhesions. Prokera was cleared by the FDA as a Class II Medical Device in 2003—nearly 20 years ago. It is indicated and has successfully been treating ocular surface damage and inflamed stroma for many years and is considered standard of care.

The placement of Prokera is reported with the Category I CPT code 65778 (Placement of Amniotic Membrane on the ocular surface; without sutures) which was established in 2011 by the AMA. The establishment of a Category I code indicates that a technology meets the following criteria:

- All devices and drugs necessary for performance of the procedure of service have received FDA clearance or approval when such is required for performance of the procedure or service.

- The procedure or service is performed by many physicians or other qualified health care professionals across the US;
- The procedure or service is performed with frequency consistent with the intended clinical use (i.e., a service for a common condition should have high volume, whereas a service commonly performed for a rare condition may have low volume);
- The procedure or service is consistent with current medical practice; and
- The clinical efficacy of the procedure or service is documented in literature, and it meets the requirements set forth in the CPT code change application.¹

Advantages of covering the use of Prokera to treat my patient's PUNCTATE KERATITIS include the fact that Prokera does not require sutures to deliver the therapeutic benefits. The advantage of a sutureless approach is that it facilitates easier treatment because it can be performed in the office setting instead of in a surgical facility, thereby providing convenience and cost savings. This sutureless procedure is performed nationwide by both ophthalmologists and optometrists to treat various ocular surface disorders, and is covered by Medicare, and most major commercial carriers, such as Aetna, Blue Cross Blue Shield, Humana, etc. It has long been recognized as standard of care to treat diseases that cause ocular surface damage or inflammation.

Published Clinical Evidence

There are many clinical publications supporting the use of Prokera to treat Superficial Punctate Keratitis (SPK), Neurotrophic Keratitis (NK), corneal ulcers and melts, Stevens-Johnson syndrome, and Persistent Epithelial Defects (PED).^{i,ii,iii,iv,v,vi,vii,viii,ix,x,xi,xii,xiii}

A retrospective review of Prokera device was reported by Cheng et al., 2018 which assessed a 48-year-old patient with a ten-year history of rheumatoid arthritis under systemic immunomodulation developed non-resolved severe ocular dryness, pain, photophobia, recurrent diffuse SPK, and blurred vision due to corneal epithelial keratopathy OD much worse than OS despite topical artificial tears, steroids, cyclosporine, autologous serum drops, punctal plugs and scleral lens for the last three years. Over the course of the first year, this patient was treated with punctal cauterization and a total of 6 CAM (Prokera Slim (PKS)), each for an average of 7.2 ± 2.3 days, for their recurrent diffuse SPK with filaments. During the first year, the average symptom-free period was 2.4 ± 0.9 months and visual acuity improvement from 20/400 to 20/200. During the next two years, she received surgical closure of puncta for recurrent punctal reopening, additional systemic immunomodulation and a total of four CAM (PKS), each for an average of 8.5 ± 2 days, for recurrent scattered SPK. By years two and three, she achieved an average symptom-free period of $6.4 \pm$ one month and visual acuity improvement from 20/200 to 20/70.^{xi}

In a clinical study published in August 2017, Thomas John, MD conducted a prospective randomized clinical trial that compared the use of Prokera to conventional maximum treatment. The overall dry eye symptoms including discomfort and visual disturbances were significantly improved in the study group over the course of the study yet remained constant in the control group. The study group demonstrated a significant increase in corneal nerve density ($12,241 \pm 5083 \mu\text{m}/\text{mm}^2$ at baseline, $16,364 \pm 3734 \mu\text{m}/\text{mm}^2$ at 1 month, and $18,827 \pm 5453 \mu\text{m}/\text{mm}^2$ at 3 months, $p = 0.015$). This was accompanied by an increase in corneal sensitivity (3.25 ± 0.6 cm at baseline, 5.2 ± 0.5 cm at 1 month, and 5.6 ± 0.4 cm at 3 months, $p < 0.001$) and corneal topography. The control group, however, remained unchanged.^{xii}

The references provided above support the safety and efficacy of the use of human Amniotic Membrane without sutures for several ocular indications, including PK. Even nerve regeneration was reported because of treatment with Prokera. The attached patient records support their medical necessity of this treatment. We ask that you authorize the use of Prokera on this patient based on their medical necessity and the proven safety and efficacy of human amniotic

¹ <https://www.ama-assn.org/practice-management/criteria-cpt-category-i-and-category-iii-codes>

membrane without sutures for ocular use, so we may move forward with the procedure. If you have any questions or require additional information regarding the procedure or patient, please do not hesitate to contact me.

Sincerely,

[Physician Name]

[Email]

[Phone]

ⁱ Morkin MI and Hamrah P. Efficacy of self- retained cryopreserved amniotic membrane for treatment of neuropathic corneal pain. *The Ocular Surface*. 2018; 16: 132-8[76]

ⁱⁱ Tighe S. (2018) Use of Amniotic Membrane in Corneal Ulcers with or without Neurotrophic Keratitis. *2018 ASCRS/ASOA Symposium and Congress*. Paper.

ⁱⁱⁱ Brocks D, Mead OG, Tighe S, Tseng SC. Self-Retained Cryopreserved Amniotic Membrane for the Management of Corneal Ulcers. *Clinical Ophthalmology*. 2020 May 26; 14:1437-43.

^{iv} Yin HY, Cheng AM, Tighe S, Kurochkin P, Nord J, Dhanireddy S, Swan R, Alpert S. Self-retained cryopreserved amniotic membrane for treating severe corneal ulcers: a comparative, retrospective control study. *Scientific Reports*. 2020 Oct 12;10(1):1-5.

^v Yeu E, Tighe S, Sheha H. Optimizing ocular surface prior to Cataract Surgery. *2017 AAO, New Orleans, LA*.

^{vi} Sheha H, Tighe S. (2018) Self-Retained Amniotic Membrane for Epithelial Basement Membrane Dystrophy. *2018 ASCRS/ASOA Symposium and Congress*. Poster.

^{vii} Cheng AMS and Tseng SCG. Self-Retained Amniotic Membrane Combined with Antiviral Therapy for Herpetic Epithelial Keratitis. *Cornea*. 2017; 36: 1383-6.

^{viii} Doll T. Cryopreserved Amniotic Membrane, Autologous Serum Eye Drops, and Tea-Tree Oil Lid Scrubs in combination for the treatment of Keratoconjunctivitis in a Staphylococcus Hypersensitive Teenager. *Journal of Dry Eye Disease*. 2017; 1: e1-e10.

^{ix} Sheha H, Tighe S, Cheng AMS and Tseng SCG. A stepping-stone in treating dendritic keratitis. *American Journal of Ophthalmology Case Reports*. 2017; 7: 55-8.

^x Harthan J and A Sicks L. Sutureless Amniotic Membranes (Prokera) for Filamentary Keratitis: A Case Series. *Journal of Dry Eye and Ocular Surface Disease*. 2019; 2: e10-e6.

^{xi} Cheng AMS, Tighe S, Sheha H and Tseng SCG. Adjunctive role of self-retained cryopreserved amniotic membrane in treating immune-related dry eye disease. *International Ophthalmology*. 2018;38: 2219-22

^{xii} John T, Tighe S, Sheha H, et al. Corneal Nerve Regeneration after Self-Retained Cryopreserved Amniotic Membrane in Dry Eye Disease. *J Ophthalmology* 2017; Volume 2017, Article ID 6404918, 10 pages. <https://doi.org/10.1155/2017/6404918>

^{xiii} McDonald M, Janik SB, Bowden FW, Chokshi A, Singer MA, Tighe S, Mead OG, Nanda S, Qazi MA, Dierker D, Shupe AT, McMurren BJ. Association of Treatment Duration and Clinical Outcomes in Dry Eye Treatment with Sutureless Cryopreserved Amniotic Membrane. *Clin Ophthalmol*. 2023;17:2697-2703

Sample Prior Authorization Request Letter

Diagnosis: Neurotrophic Keratitis

Please include physician letterhead on Prior Authorization Letters

[Date]

[Payor Contact]

[Title]

[Address]

[City, State, Zip]

Re: [Patient Name]

[Patient Identification Number]

[Date of Service]

Dear [Payor Contact]:

I am writing on behalf of my patient, [Insert patient name], to request [Payor name] cover the use of Prokera® to treat their Neurotrophic Keratitis (NK).

Patient History

As you know, this patient has a long history of [dry eye, incomplete blinking, etc.—ADD PATIENT-SPECIFIC HISTORY that led to NK]. If allowed to progress, my patient's extreme neurotrophic keratitis and dry eyes is in danger of developing into perforated corneal ulcers. To date, [list previous treatments tried and failed] have been tried to resolve [patient's name] condition, but all have failed. As they have decreasing corneal sensation and worsening symptoms, I determined that they require the application of a Prokera Cryopreserved Amniotic Membrane (CAM). This patient has a severe case of Neurotrophic Keratitis (NK) that studies show can get clinically significant benefits from the Prokera application.

[Additional patient history, including rationale as to why this is the preferred treatment option to treat the condition of this patient (i.e., patient is not a surgical candidate). Physician may also want to expand upon his/her experience with prior use of Prokera.]

NK is a corneal degenerative disease characterized by a reduction or absence of corneal sensitivity. In NK, corneal innervation by the trigeminal nerve is impaired. Partial or complete loss of corneal sensation may result in epithelial keratopathy, epithelial defect, stromal ulceration, and eventually corneal perforation. Clinical presentation of NK ranges from subtle corneal surface irregularities to corneal melting and perforation.

The management of NK is required to promote corneal healing and avoid complications. Unlike many treatments, Prokera is inserted by a medical professional, and stays in the eye for 3-30 days depending on physician recommendation. It does not require the patient to administer drops or other medications to the eye at two-hour intervals, over the course of 8-weeks, etc., so patient compliance is expected to be greater.

Published Clinical Evidence

There are many clinical publications supporting the use of Prokera to treat numerous ocular diseases including NK, corneal ulcers and melts, Stevens-Johnson syndrome, and PEDs. In a 2018 retrospective study called *The Ocular Surface*, ten eyes of nine patients with diagnosis of neuropathic corneal pain were treated with Prokera Slim (PKS) (n = 8) or Prokera Clear (PKCLR) (n = 2). Pain severity improved by 73 ± 8 percent (from 6.3 ± 0.8 to 1.9 ± 0.6 , $p = 0.0003$) after retention for 6.4 ± 1.1 days. Despite shorter retention for 4.0 ± 0.7 days in patients with ring dysesthesia (four eyes) or premature implant disengagement (two eyes), pain severity still improved by 63.1 ± 12.5 percent (from 6.8 ± 1.0 to 2.4 ± 0.9 , $p = 0.009$). During a follow-up of 9.3 ± 0.8 months, two patients reported recurrence of pain after 2.3 and 9.6 months respectively. In Vivo Confocal Microscopy (IVCM) showed a 36.6 ± 17.6 percent increase in total nerve density, from $17,700.9 \pm 1315.7$ to $21,891.3 \pm 2040.5 \mu\text{m}/\text{mm}^2$ ($p = 0.047$), while the fellow PKS/PKCLR-untreated eyes did not show a significant interval change. Dendritiform cell density decreased from 46.0 ± 8.2 to 32.0 ± 6.0 cells/ mm^2 ($p = 0.01$).^{i,ii,iii,iv,v,vi,vii,viii,ix,x,xi}

Additionally, in a prospective, randomized clinical trial by Thomas John, MD published in the *Journal of Ophthalmology* in 2017, 20 subjects with dry eye disease were randomly assigned to receive PKS in one eye (n=10) or conventional treatment (n=10). For the study group, PKS was inserted in the office under topical anesthesia with 0.5 percent proparacaine hydrochloride eye drops. After placement, the subjects were asked to continue topical medications as needed and return three to five days later to remove the PKS. Subjects in the control group were asked to continue their conventional maximum treatment throughout the duration of the study including artificial tears, cyclosporine A, serum tears, antibiotics, steroids, and nonsteroidal anti-inflammatory medications. The results of that trial showed that in the study group pain score, Standard Patient Evaluation of Eye Dryness Questionnaire (SPEED) score, corneal staining score, and Dry Eye Workshop (DEWS) score all significantly decreased from baseline at both one- and three-months ($p < 0.05$). In contrast, none of these showed significant improvement in the control group. **IVCM showed a significant increase in corneal nerve density in the study group** ($12,241 \pm 5083 \mu\text{m}/\text{mm}^2$ at baseline, $16,364 \pm 3734 \mu\text{m}/\text{mm}^2$ at one-month, and $18,827 \pm 5453 \mu\text{m}/\text{mm}^2$ at three-months, $p = 0.015$) but was unchanged in the control. This improvement was accompanied with a significant increase in corneal sensitivity (3.25 ± 0.6 cm at baseline, 5.2 ± 0.5 cm at one-month, and 5.6 ± 0.4 cm at three-months, $p < 0.001$) and corneal topography only in the study group.^{xi}

Other clinical evidence to support the effectiveness of using Prokera to treat different corneal diseases including NK is listed in the endnote. Many patients received a significant clinical benefit from even one application of Prokera. For this reason, I have determined that Prokera would be the next logical step toward treating my patient.

Based on the information provided, and on behalf of [patient's name], I am asking that you allow coverage for the Prokera, so your member may be treated and receive the same clinical benefits that others have received from Prokera. With this treatment, we expect dramatic improvements in their symptoms that they would not have had without Prokera.

Should you require additional information, please do not hesitate to contact my office at the information below.

Sincerely,

[Doctor Name]

[Title/Specialty]

[Email address]

ⁱ Morkin MI and Hamrah P. Efficacy of self-retained cryopreserved amniotic membrane for treatment of neuropathic corneal pain. *The Ocular Surface*. 2018; 16: 132-8.

ⁱⁱ Tighe S. (2018) Use of Amniotic Membrane in Corneal Ulcers with or without Neurotrophic Keratitis. 2018 ASCRS/ASOA Symposium and Congress. Paper.

ⁱⁱⁱ Brocks D, Mead OG, Tighe S, Tseng SC. Self-Retained Cryopreserved Amniotic Membrane for the Management of Corneal Ulcers. *Clinical Ophthalmology*. 2020 May 26; 14:1437-43.

^{iv} Yin HY, Cheng AM, Tighe S, Kurochkin P, Nord J, Dhanireddy S, Swan R, Alpert S. Self-retained cryopreserved amniotic membrane for treating severe corneal ulcers: a comparative, retrospective control study. *Scientific Reports*. 2020 Oct 12;10(1):1-5.

^v Yeu E, Tighe S, Sheha H. Optimizing ocular surface prior to Cataract Surgery. 2017 AAO, New Orleans, LA.

^{vi} Sheha H, Tighe S. (2018) Self-Retained Amniotic Membrane for Epithelial Basement Membrane Dystrophy. 2018 ASCRS/ASOA Symposium and Congress. Poster.

^{vii} Cheng AMS and Tseng SCG. Self-Retained Amniotic Membrane Combined with Antiviral Therapy for Herpetic Epithelial Keratitis. *Cornea*. 2017; 36: 1383-6.

-
- ^{viii} Doll T. Cryopreserved Amniotic Membrane, Autologous Serum Eye Drops, and Tea-Tree Oil Lid Scrubs in combination for the treatment of Keratoconjunctivitis in a Staphylococcus Hypersensitive Teenager. *Journal of Dry Eye Disease*. 2017; 1: e1-e10.
- ^{ix} Sheha H, Tighe S, Cheng AMS and Tseng SCG. A stepping-stone in treating dendritic keratitis. *American Journal of Ophthalmology Case Reports*. 2017; 7: 55-8.
- ^x Harthan J and A Sicks L. Sutureless Amniotic Membranes (Prokera) for Filamentary Keratitis: A Case Series. *Journal of Dry Eye and Ocular Surface Disease*. 2019; 2: e10-e6.
- ^{xi} John T, Tighe S, Sheha H, et al. Corneal Nerve Regeneration after Self-Retained Cryopreserved Amniotic Membrane in Dry Eye Disease. *Journal of Ophthalmology*. 2017; 2017: 6404918

Sample Prior Authorization Request Letter

Diagnosis: Recurrent Corneal Erosion

Please include physician letterhead on Prior Authorization Letters

[Date]

[Payor Contact]

[Title]

[Address]

[City, State, Zip]

Re: [Patient Name]

[Patient Identification Number]

[Date of Service]

Dear [Payor Contact]:

I am writing on behalf of my patient, [Insert patient name], to request [Payor name] cover the use of Prokera® to treat their Recurrent Corneal Erosion (RCE).

Patient History

As you know, this patient has a long history of [dry eye, incomplete blinking, etc.—ADD PATIENT-SPECIFIC HISTORY that led to RCE]. If allowed to progress, my patient's RCE is in danger of developing additional complications including perforated corneal ulcers. To prevent progression, I have determined that they require the application of a Prokera Cryopreserved Amniotic membrane (CAM). This patient has a severe case of RCE that studies show, can get clinically significant benefits from the Prokera application.

[Additional patient history, including rationale as to why this is the preferred treatment option to treat the condition of this patient (i.e., patient is not a surgical candidate). Physician may also want to expand upon his/her experience with prior use of Prokera.]

RCE is a common cause of disabling ocular symptoms and predisposes the cornea to infection. In this condition the surface skin of the cornea (the clear window of the eye) breaks down, causing sharp pain, watering, and sometimes blurred vision. It may be due to a previous mild injury (corneal abrasion) or to a condition known as a dystrophy in which the surface of the cornea is unusually delicate. The condition may recur over weeks or months. In the case of this patient, they developed RCE over [xxx weeks/ months/ years, etc.] and since onset, we have treated it by reducing friction between the eye and the eyelids, using [list treatments, i.e., lubricating drops and/or ointments], to encourage complete healing of the eye surface. Unfortunately, other measures are needed, as previous treatments have failed and not offered full resolution of the RCE.

It is my professional opinion that to prevent further progression, this patient requires the application of Prokera to treat their corneal erosion.

Published Clinical Evidence

There are many clinical publications supporting the use of Prokera to treat numerous ocular diseases including Recurrent Corneal Erosion (RCE), Neurotrophic Keratitis (NK), corneal ulcers and melts, Stevens-Johnson syndrome, and Persistent Epithelial Defects (PEDs).

In a retrospective series by Huang YS published in the *Journal of Clinical and Experimental Ophthalmology*, 11 eyes of nine consecutive patients with recurrent corneal erosion received epithelial debridement and placement of Prokera. After debridement and placement of Prokera, complete epithelialization was noted in all eyes in four to seven days. During the follow up of 13.7 ± 2.2 months, one eye recurred and required repeated treatment. Afterwards, all eyes were asymptomatic and regained a smooth and stable corneal epithelium. Best-corrected visual acuity was improved to at least 20/30 in all six eyes complaining of blurry vision and involving the visual axis.ⁱ

In a Prospective Comparative Study over one-month, Dr NR Desai, did a comparison of Cryopreserved Amniotic Membrane (CAM) and bandage contact lens in their ability to provide high-quality healing after Superficial Keratectomy (SK). SK was performed at slit lamp for ten patients with either bilateral Recurrent Erosion Syndrome (RES), Epithelial Basement Membrane Disease (EBMD), or Salzmann Nodular Degeneration (SND). The eye with more severe disease was treated with PKS, while the eye with less severe disease was treated with Bandage Contact Lens (BCL). Both treatment groups received the same regimen of topical drops. Treatment with PKS resulted in complete re-epithelialization of corneal wounds faster than with BCL, in a net gain of two lines of Best Corrected Visual Acuity (BCVA) compared with a net loss of BCVA with BCL at Day-30, and in wound healing without sub-epithelial hazing or scarring frequently seen with BCL. There was one adverse event in the BCL-treated eye during the study and none in the PKS-treated eyes. There was no statistical significance in pain or discomfort between PKS and BCL ($P=0.368$).ⁱⁱ

There are many clinical publications supporting the use of Prokera® to treat Recurrent Corneal Erosion (RCE), Neurotrophic Keratitis (NK), corneal ulcers and melts, Stevens-Johnson syndrome, and Persistent Epithelial Defects (PED).^{iii,iv,v,vi,vii,viii,ix,x,xi,xii}

Based on the information provided, and on behalf of [patient's name], I am asking that you allow coverage for the Prokera to treat their RCE, so your member may receive the same clinical benefits that others have received with the use of Prokera. With this treatment, we expect dramatic improvements in their symptoms that they would not achieve without treatment with Prokera.

Should you require additional information, please do not hesitate to contact my office at the information below.

Sincerely,

[Doctor Name]

[Title/Specialty]

[Email address]

ⁱ Huang YS, H; Tseng S.G. Self-retained Amniotic Membrane Transplantation for Recurrent Corneal Erosion. *Journal of Clinical and Experimental Ophthalmology*. 2013; 4:272.

ⁱⁱ Desai NR. A comparison of cryopreserved amniotic membrane and bandage contact lens in their ability to provide high-quality healing after superficial keratectomy. *Review of Ophthalmology*. 2014.

ⁱⁱⁱ Morkin MI and Hamrah P. Efficacy of self-retained cryopreserved amniotic membrane for treatment of neuropathic corneal pain. *The Ocular Surface*. 2018; 16: 132-8

^{iv} Tighe S. (2018) Use of Amniotic Membrane in Corneal Ulcers with or without Neurotrophic Keratitis. 2018 ASCRS/ASOA Symposium and Congress. Paper.

^v Brocks D, Mead OG, Tighe S, Tseng SC. Self-Retained Cryopreserved Amniotic Membrane for the Management of Corneal Ulcers. *Clinical Ophthalmology*. 2020 May 26; 14:1437-43.

^{vi} Yin HY, Cheng AM, Tighe S, Kurochkin P, Nord J, Dhanireddy S, Swan R, Alpert S. Self-retained cryopreserved amniotic membrane for treating severe corneal ulcers: a comparative, retrospective control study. *Scientific Reports*. 2020 Oct 12;10(1):1-5.

^{vii} Yeu E, Tighe S, Sheha H. Optimizing ocular surface prior to Cataract Surgery. 2017 AAO, New Orleans, LA.

^{viii} Sheha H, Tighe S. (2018) Self-Retained Amniotic Membrane for Epithelial Basement Membrane Dystrophy. 2018 ASCRS/ASOA Symposium and Congress. Poster.

^{ix} Cheng AMS and Tseng SCG. Self-Retained Amniotic Membrane Combined with Antiviral Therapy for Herpetic Epithelial Keratitis. *Cornea*. 2017; 36: 1383-6.

^x Doll T. Cryopreserved Amniotic Membrane, Autologous Serum Eye Drops, and Tea-Tree Oil Lid Scrubs in combination for the treatment of Keratoconjunctivitis in a Staphylococcus Hypersensitive Teenager. *Journal of Dry Eye Disease*. 2017; 1: e1-e10.

^{xi} Sheha H, Tighe S, Cheng AMS and Tseng SCG. A stepping-stone in treating dendritic keratitis. *American Journal of Ophthalmology Case Reports*. 2017; 7: 55-8.

^{xii} Harthan J and A Sicks L. Sutureless Amniotic Membranes (Prokera) for Filamentary Keratitis: A Case Series. *Journal of Dry Eye and Ocular Surface Disease*. 2019; 2: e10-e6.

Sample Prior Authorization Request Letter

Diagnosis: Persistent Epithelial Defect

Please include physician letterhead on Prior Authorization Letters

[Date]

[Payor Contact]

[Title]

[Address]

[City, State, Zip]

Re: [Patient Name]

[Patient Identification Number]

[Date of Service]

Dear [Payor Contact]:

I am writing on behalf of my patient, [Insert patient name], to request [Payor name] cover the use of Prokera® to treat their Persistent Epithelial Defect (PED).

Patient History

As you know, this patient has a long history of [dry eye, incomplete blinking, etc.—ADD PATIENT-SPECIFIC HISTORY that has now progressed into PED]. If left untreated, PEDs can result in significant complications, including infection and vision loss. To date, [list previous treatments tried and failed] have been tried in an attempt to resolve [patient's name] condition, but all have failed. As my patient suffers a non-healing, or persistent, epithelial defect, it is causing them [compromised vision, ocular discomfort, etc. ADD PT-SPECIFIC SYMPTOMS HERE]. This non-healing corneal epithelial defect can have other deleterious consequences, including infection, scarring, melting, and perforation. Therefore, I have determined that they require the application of a Prokera Cryopreserved Amniotic Membrane (CAM). Prokera will help restore my patient's cornea and return their eye to a normal, healthy state. Prokera which contains an essential effector protein complex, helps rapidly restore the cornea's own healing capabilities through regenerative healing. Studies have shown that Prokera can accelerate healing and offer clinically significant benefits with application.ⁱ

[Additional patient history, including rationale as to why this is the preferred treatment option to treat the condition of this patient (i.e., patient is not a surgical candidate). Physician may also want to expand upon their experience with prior use of Prokera.]

In a retrospective case-control study of 24 eyes published in Scientific Reports, Oct 12, 2020, all patients received Standard of Care (SOC) including corneal scraping and microbial culture before broad-spectrum antimicrobial antibiotics. Once culture confirmed, target antimicrobial therapy was given. 11 patients received Prokera Slim (PKS) in addition to SOC. PKS left for at least 5-days. The results for patients with placement of PKS had significantly faster epithelialization within 3.56 ± 1.78 weeks vs 5.87 ± 2.20 weeks ($p = 0.01$). Placement of PKS helped achieve improved epithelialization rates (72.7% vs 23.1% $p = 0.04$). PKS group had clinically significant BCSVA (>3 lines) improvement (81.8% vs 38.4%, $p = 0.047$) compared to SOC. PKS group had clinically significant total VA improvement (logMAR 0.7 ± 0.6 vs 1.6 ± 0.9 , $p = 0.016$) compared to SOC. Some complaints of foreign body sensation.ⁱⁱ

In a retrospective review published in May 2020, 13 eyes of 13 patients with recalcitrant corneal ulcers, 9 (69%) of which progressed from Neurotrophic Keratitis (NK), were treated with Prokera. These patients had failed conventional treatments including artificial tears ($n = 11$), antibiotics ($n = 11$), ointment ($n = 11$), steroids ($n = 6$), and antivirals ($n = 3$).

Follow-ups were of ≥ 6 mo. Self-retained CAM (Prokera Slim) was placed for 6.8 ± 3.4 days with antibiotics. 3 cases (31%) were subsequently treated with Bandage Contact Lens (BCL) and 1 case was subsequently treated with tarsorrhaphy. The mean number of devices was 1.5 ± 0.8 . The result: 13/13 ulcers healed in a median of 14 d (range 4–43). Significant improvements in discomfort, corneal staining, and corneal signs at 1-week, 1-month, 3-months, and 6-months ($p < 0.05$). One case of recurrence. No adverse effects.ⁱⁱⁱ

There are many clinical publications supporting the use of Prokera to treat Persistent Epithelial Defect (PED), Recurrent Corneal Erosion (RCE), Neurotrophic Keratitis (NK), corneal ulcers and melts, and Stevens-Johnson syndrome.^{iv,v,vi,vii,viii,ix,x,xi,xii,xiii, xiv}

Based on those studies and information included in this correspondence, on behalf of [patient's name], I am asking that you allow coverage for the Prokera to treat their PED, so your member may receive the same clinical benefits that others have received with the use of Prokera. With this treatment, we expect dramatic improvements in their symptoms that they would not achieve without treatment with Prokera.

Should you require additional information, please do not hesitate to contact my office at the information below.

Sincerely,

[Doctor Name]

[Title/Specialty]

[Email address]

ⁱ Cheng AM, Zhao D, Chen R, et al. Accelerated restoration of ocular surface health in dry eye disease by self-retained cryopreserved amniotic membrane. *Ocul Surf*. 2016;14(1):56–63.

ⁱⁱ Yin HY, Cheng AM, Tighe S, Kurochkin P, Nord J, Dhanireddy S, Swan R, Alpert S. Self-retained cryopreserved amniotic membrane for treating severe corneal ulcers: a comparative, retrospective control study. *Scientific Reports*. 2020 Oct 12;10(1):1–5.

ⁱⁱⁱ Brocks D, Mead OG, Tighe S, Tseng SC. Self-Retained Cryopreserved Amniotic Membrane for the Management of Corneal Ulcers. *Clinical Ophthalmology*. 2020 May 26; 14:1437–43.

^{iv} Morkin MI and Hamrah P. Efficacy of self- retained cryopreserved amniotic membrane for treatment of neuropathic corneal pain. *The Ocular Surface*. 2018; 16: 132–8[76]

^v Tighe S. (2018) Use of Amniotic Membrane in Corneal Ulcers with or without Neurotrophic Keratitis. 2018 ASCRS/ASOA Symposium and Congress. Paper.

^{vi} Brocks D, Mead OG, Tighe S, Tseng SC. Self-Retained Cryopreserved Amniotic Membrane for the Management of Corneal Ulcers. *Clinical Ophthalmology*. 2020 May 26; 14:1437–43.

^{vii} Yin HY, Cheng AM, Tighe S, Kurochkin P, Nord J, Dhanireddy S, Swan R, Alpert S. Self-retained cryopreserved amniotic membrane for treating severe corneal ulcers: a comparative, retrospective control study. *Scientific Reports*. 2020 Oct 12;10(1):1–5.

^{viii} Yeu E, Tighe S, Sheha H. Optimizing ocular surface prior to Cataract Surgery. 2017 AAO, New Orleans, LA.

^{ix} Sheha H, Tighe S. (2018) Self-Retained Amniotic Membrane for Epithelial Basement Membrane Dystrophy. 2018 ASCRS/ASOA Symposium and Congress. Poster.

^x Cheng AMS and Tseng SCG. Self-Retained Amniotic Membrane Combined with Antiviral Therapy for Herpetic Epithelial Keratitis. *Cornea*. 2017; 36: 1383–6.

^{xi} Doll T. Cryopreserved Amniotic Membrane, Autologous Serum Eye Drops, and Tea-Tree Oil Lid Scrubs in combination for the treatment of Keratoconjunctivitis in a Staphylococcus Hypersensitive Teenager. *Journal of Dry Eye Disease*. 2017; 1: e1–e10.

^{xii} Sheha H, Tighe S, Cheng AMS and Tseng SCG. A stepping-stone in treating dendritic keratitis. *American Journal of Ophthalmology Case Reports*. 2017; 7: 55–8.

^{xiii} Harthan J and A Sicks L. Sutureless Amniotic Membranes (Prokera) for Filamentary Keratitis: A Case Series. *Journal of Dry Eye and Ocular Surface Disease*. 2019; 2: e10–e6.

^{xiv} Lam SS, Sklar BA, Schoen M, Rapuano CJ. Severe ocular alkali injury managed with an externally sutured amniotic membrane and customized symblepharon ring. *Taiwan J Ophthalmol*. 2022 Dec 2;13(1):101–105. doi: 10.4103/2211-5056.362597. PMID: 37252174; PMCID: PMC10220433.

Sample Prior Authorization Request Letter

Diagnosis: Severe Dry Eye

Please include physician letterhead on Prior Authorization Letters

[Date]

[Payor Contact]

[Title]

[Address]

[City, State, Zip]

Re: [Patient Name]

[Patient Identification Number]

[Date of Service]

Dear [Payor Contact]:

I am writing on behalf of my patient, [Insert patient name], to request [Payor name] cover the use of Prokera® to treat their symptoms of Severe Dry Eye.

Patient History

As you know, this patient has a long history of [dry eye, incomplete blinking, etc.—ADD PATIENT-SPECIFIC HISTORY] and now suffers severe dry eye. If left untreated, their dry eye symptoms can result in significant complications, including eye infection, damage to the surface of the eyes, and decreased quality of life. To date, [list previous treatments tried and failed] have been tried to resolve [patient's name] condition, but all have failed. As my patient suffers from severe dry eye, it is causing them [compromised vision, ocular discomfort, etc. ADD PT-SPECIFIC SYMPTOMS HERE]. Therefore, I have determined that they require the application of a Prokera Cryopreserved Amniotic Membrane (CAM). Prokera will help restore my patient's cornea and return their eye to a normal, healthy state, thereby relieving them of the symptoms of severe dry eye. Prokera which contains an essential effector protein complex, helps rapidly restore the cornea's own healing capabilities through regenerative healing. Studies have shown that Prokera can accelerate healing and offer clinically significant benefits with application.ⁱ

[Additional patient history, including rationale as to why this is the preferred treatment option to treat the condition of this patient (i.e., patient is not a surgical candidate). Physician may also want to expand upon their experience with prior use of Prokera.]

In a retrospective study published in 2016, ten patients were treated with Prokera Slim (PKS), a self-retained CAM for moderate-to-severe dry eye refractory to conventional maximal medical treatments. Patients' symptoms, use of medications, conjunctival inflammation, corneal staining, and visual acuity were compared before and after treatment. **The result** showed PKS was placed in 15 eyes of the ten patients for 4.9 ± 1.5 days. All patients experienced symptomatic relief for a period of 4.2 ± 4.7 months ($p < .001$). Such improvement was accompanied by reduction of OSDI scores ($p < .001$), use of topical medications ($p < .001$), conjunctival hyperemia ($p < .001$), corneal staining ($p < .001$), and improvement of the visual acuity ($p = .06$). Linear regression analysis estimated that the optimal duration of PKS placement was 5-days to achieve an average symptom-free duration of 4-months in patients with dry eye. Surprisingly, PKS placement also generated improvement in the contralateral eyes.ⁱⁱ

In a 3-month, randomized clinical trial, published in the *Journal of Ophthalmology* in 2017, 20 subjects with dry eye disease were randomly assigned to receive PKS in one eye ($n=10$) or conventional treatment ($n=10$). For the study group, PKS was inserted in the office under topical anesthesia with 0.5 percent proparacaine hydrochloride eye drops. After placement, the subjects were asked to continue topical medications as needed and return 3-5 days later to remove the

PKS. Subjects in the control group were asked to continue their conventional maximum treatment throughout the duration of the study including artificial tears, cyclosporine A, serum tears, antibiotics, steroids, and nonsteroidal anti-inflammatory medications. During the trial, changes in signs and symptoms (VAS pain, SPEED questionnaire, DEWS), corneal sensitivity, topography, and In Vivo Confocal Microscopy (IVCM) were evaluated at baseline 1-month, and 3-months. **The results:** In the study group pain score, SPEED score, corneal staining score, and DEWS score all significantly decreased from baseline at both 1-month, and 3-months ($p < 0.05$). In contrast, none of these showed significant improvement in the control group. IVCM showed a significant increase in corneal nerve density in the study group ($12,241 \pm 5083 \mu\text{m}/\text{mm}^2$ at baseline, $16,364 \pm 3734 \mu\text{m}/\text{mm}^2$ at 1-month, and $18,827 \pm 5453 \mu\text{m}/\text{mm}^2$ at 3-months, $p = 0.015$) but was unchanged in the control. This improvement was accompanied with a significant increase in corneal sensitivity ($3.25 \pm 0.6 \text{ cm}$ at baseline, $5.2 \pm 0.5 \text{ cm}$ at 1-month, and $5.6 \pm 0.4 \text{ cm}$ at 3-months, $p < 0.001$) and corneal topography only in the study group.ⁱⁱⁱ

Another retrospective study over 3-months reviewed the medical records of patients with Dry Eye Disease (DED) associated with ocular surface disorders who were treated with Cryopreserved Amniotic Membrane (CAM) as a temporary bandage (PKS before June 1, 2016, and completed 1-week, 1-month, and 3-months of follow-up were reviewed. Inclusion criteria also included subjects aged 21 years and older who had moderate- to-severe DED, grades two to four, as defined by the Report of the International Dry Eye Workshop (DEWS). A total of 97 eyes of 84 patients that exhibited severe dry eye (DEWS 3.25 ± 0.5) despite maximal medical treatments received AM placement (PKS). Patients manifested with Superficial Punctate Keratitis (SPK) (86 percent), Filamentary Keratitis (13 percent), Exposure Keratitis (19 percent), Neurotrophic Keratitis (NK) (two percent, and corneal epithelial defect (seven percent). The primary outcome was the change in dry eye workshop (DEWS) score after treatment. After CAM treatment for 5.4 ± 2.8 days, 74 (88 percent) patients demonstrated an improved ocular surface along with a notable reduction of the severity as the overall DEWS score was significantly reduced from 3.25 ± 0.5 at baseline to 1.44 ± 0.6 at 1-week, 1.45 ± 0.6 at 1-month, and 1.47 ± 0.6 at 3-months ($p < 0.001$). Ten eyes (ten percent) required repeated treatment to complete healing. Apart from discomfort during CAM placement, there were no adverse events.^{iv}

There are many clinical publications supporting the use of Prokera to treat Dry Eye Disease (DED), Recurrent Corneal Erosion (RCE), Neurotrophic Keratitis (NK), corneal ulcers and melts, and Stevens-Johnson syndrome, etc.^{v,vi,vii,viii,ix,x,xi,xii,xiii,xiv,xv}

Based on those studies and information included in this correspondence, and on behalf of [patient's name], I am asking that you allow coverage for the Prokera to treat their severe dry eye, so your member may receive the same clinical benefits that others have received with the use of Prokera. With this treatment, we expect dramatic improvements in their symptoms that they would not achieve without treatment with Prokera.

Should you require additional information, please do not hesitate to contact my office at the information below.

Sincerely,

[Doctor Name]

[Title/Specialty]

[Email address]

ⁱ Cheng AM, Zhao D, Chen R, et al. Accelerated restoration of ocular surface health in dry eye disease by self-retained cryopreserved amniotic membrane. *Ocul Surf*. 2016;14(1):56-63.

ⁱⁱ Cheng AM, Zhao D, Chen R, et al. Accelerated Restoration of Ocular Surface Health in Dry Eye Disease by Self-Retained Cryopreserved Amniotic Membrane. *The Ocular Surface*. 2016; 14: 56-63

ⁱⁱⁱ John T, Tighe S, Sheha H, et al. Corneal Nerve Regeneration after Self-Retained Cryopreserved Amniotic Membrane in Dry Eye Disease. *Journal of Ophthalmology*. 2017; 2017: 6404918

^{iv} McDonald MB, Sheha H, Tighe S, et al. Treatment outcomes in the Dry Eye Amniotic Membrane (DREAM) study. *Journal of Clinical Ophthalmology* (Auckland, NZ). 2018; 12: 677-81

^v Morkin MI and Hamrah P. Efficacy of self-retained cryopreserved amniotic membrane for treatment of neuropathic corneal pain. *The Ocular Surface*. 2018; 16: 132-8

^{vi} Tighe S. (2018) Use of Amniotic Membrane in Corneal Ulcers with or without Neurotrophic Keratitis. 2018 ASCRS/ASOA Symposium and Congress. Paper.

^{vii} Brooks D, Mead OG, Tighe S, Tseng SC. Self-Retained Cryopreserved Amniotic Membrane for the Management of Corneal Ulcers. *Clinical Ophthalmology*. 2020 May 26; 14:1437-43.

-
- ^{viii} Yin HY, Cheng AM, Tighe S, Kurochkin P, Nord J, Dhanireddy S, Swan R, Alpert S. Self-retained cryopreserved amniotic membrane for treating severe corneal ulcers: a comparative, retrospective control study. *Scientific Reports*. 2020 Oct 12;10(1):1-5.
- ^{ix} Yeu E, Tighe S, Sheha H. Optimizing ocular surface prior to Cataract Surgery. 2017 AAO, New Orleans, LA.
- ^x Sheha H, Tighe S. (2018) Self-Retained Amniotic Membrane for Epithelial Basement Membrane Dystrophy. 2018 ASCRS/ASOA Symposium and Congress. Poster.
- ^{xi} Cheng AMS and Tseng SCG. Self-Retained Amniotic Membrane Combined with Antiviral Therapy for Herpetic Epithelial Keratitis. *Cornea*. 2017; 36: 1383-6.
- ^{xii} Doll T. Cryopreserved Amniotic Membrane, Autologous Serum Eye Drops, and Tea-Tree Oil Lid Scrubs in combination for the treatment of Keratoconjunctivitis in a Staphylococcus Hypersensitive Teenager. *Journal of Dry Eye Disease*. 2017; 1: e1-e10.
- ^{xiii} Sheha H, Tighe S, Cheng AMS and Tseng SCG. A stepping-stone in treating dendritic keratitis. *American Journal of Ophthalmology Case Reports*. 2017; 7: 55-8.
- ^{xiv} Harthan J and A Sicks L. Sutureless Amniotic Membranes (Prokera) for Filamentary Keratitis: A Case Series. *Journal of Dry Eye and Ocular Surface Disease*. 2019; 2: e10-e6.
- ^{xv} McDonald M, Janik SB, Bowden FW, Chokshi A, Singer MA, Tighe S, Mead OG, Nanda S, Qazi MA, Dierker D, Shupe AT, McMurren BJ. Association of Treatment Duration and Clinical Outcomes in Dry Eye Treatment with Sutureless Cryopreserved Amniotic Membrane. *Clin Ophthalmol*. 2023;17:2697-2703

Sample Prior Authorization Request Letter

Diagnosis: Corneal Abrasion

Please include physician letterhead on Prior Authorization Letters

[Date]

[Payor Contact]

[Title]

[Address]

[City, State, Zip]

Re: [Patient Name]

[Patient Identification Number]

[Date of Service]

Dear [Payor Contact]:

I am writing on behalf of my patient, [Insert patient name], to request [Payor name] cover the use of Prokera® to treat their Corneal Abrasion. While many corneal abrasions heal in 24 to 72 hours with topical ointments, NSAIDs, topical prophylactic antibiotics, and Bandage Contact Lenses (BCLs) in some cases, some patients do not heal and require advanced therapy.

In the case of this patient, we treated their abrasion for XXXXX days with no clinical improvement. Additionally, they have significant history of [LIST conditions that may have impeded healing, such as dry eye disease, meibomian gland dysfunction, etc.] that has affected the healing process. I determined the application of Prokera to be an appropriate next step in their treatment protocol to ensure proper re-epithelialization of their injured eye. I also considered my patient's history of XXXXXXXX LIST OTHER PERTINENT HISTORY, in determining the medical necessity of Prokera Cryopreserved Amniotic Membrane (CAM).

Patient History

This patient has a history of [ADD PATIENT-SPECIFIC HISTORY that slows/prevents healing of their corneal abrasion injury, XXX, and XXXXX, etc.]. My patient's corneal abrasion has delayed healing, which can lead to additional complications, continued pain, and disruption in their activities of daily living. To promote healing and prevent it from possible worsening, I have determined that they required the application of a Prokera amniotic membrane.

[Additional patient history, including rationale as to why this is the preferred treatment option to treat the condition of this patient. Physician may also want to expand upon their experience with prior use of Prokera.]

Published Clinical Evidence – Excerpt from: Pickleball Associated Abrasion and Iritis: A Case Study

Mariam Alkawally, OD, MS; Vin T. Dang, OD, FAAO

After corneal trauma, a repair cascade soon begins which involves the production of cytokines, growth factors, and interleukins by the exposed stromal keratocytes, adjacent corneal

epithelium, and lacrimal glands.^{1,2} Like autologous serum, amniotic membranes (AM), which are obtained from placental membrane, contain neurotrophic and growth factors, however they also contain more anti-inflammatory factors, and are therefore used to augment the corneal healing process³. AM has been successfully used in a variety of conditions, including neurotrophic keratitis⁴, recurrent epithelial erosions⁵, high-risk corneal grafts⁶, partial and total stem cell deficiency⁷, and in corneal nerve regeneration in dry eye disease⁸. There are no studies comparing the efficacy of AM compared to BCL in incidences of traumatic corneal abrasions. In post-PRK patients, cryopreserved AM sped up corneal re-epithelization one day after surgery; however, it was not faster than a bandage contact lens in hastening complete re-epithelization or reduction of corneal haze^{9,10}. Unlike soft BCL however, transplanted amniotic membrane was not shown to increase incidence of microbial keratitis¹¹. Although both autologous serum and AM seem to have similar compounds, AM also contains more stem cells and anti-inflammatory effects that are not as common in autologous serum. There are not many studies comparing the two, however in one study comparing the efficacy in Neurotrophic Keratitis, AM seemed to outperform autologous serum in deep ulcers with postherpetic neurotrophic keratitis.¹² In our case, since the patient had history of dry eye disease, and since we needed to cover the exposed stroma to prevent lid shearing forces, we opted for the amniotic membrane.

Based on the information provided, and on behalf of [patient's name], I am asking that you allow coverage for the Prokera in this case, so your member may receive the same clinical benefits that others have received with the use of Prokera. With this treatment, we expect dramatic improvements in their symptoms that they would not achieve without treatment with Prokera.

Should you require additional information, please do not hesitate to contact my office at the information below.

Sincerely,

[Doctor Name]

[Title/Specialty]

[Email address]

¹ Baldwin HC, Marshall J. Growth factors in corneal wound healing following refractive surgery: a review. *Acta Ophthalmologica Scandinavica*. 2002;80(3):238-247.

² Vlasov A, Sia RK, Ryan DS, et al. Sutureless cryopreserved amniotic membrane graft and wound healing after photorefractive keratectomy. *Journal of Cataract & Refractive Surgery*. 2016;42(3):435-443.

³ Vlasov A, Sia RK, Ryan DS, et al. Sutureless cryopreserved amniotic membrane graft and wound healing after photorefractive keratectomy. *Journal of Cataract & Refractive Surgery*. 2016;42(3):435-443.

⁴ Suri K, Kosker M, Raber IM, et al. Sutureless amniotic membrane ProKera for ocular surface disorders: short-term results. *Eye & contact lens*. 2013;39(5):341-347.

⁵ Pachigolla G, Prasher P, Di Pascuale MA, McCulley JP, McHenry JG, Mootha VV. Evaluation of the role of ProKera in the management of ocular surface and orbital disorders. *Eye & contact lens*. 2009;35(4):172-175.

⁶ Shanbhag SS, Hall L, Chodosh J, Saeed HN. Long-term outcomes of amniotic membrane treatment in acute Stevens- Johnson syndrome/toxic epidermal necrolysis. *The ocular surface*. 2020;18(3):517-522.

⁷ Pachigolla G, Prasher P, Di Pascuale MA, McCulley JP, McHenry JG, Mootha VV. Evaluation of the role of ProKera in the management of ocular surface and orbital disorders. *Eye & contact lens*. 2009;35(4):172-175.

⁸ John T, Tighe S, Sheha H, et al. Corneal nerve regeneration after self-retained cryopreserved amniotic membrane in dry eye disease. *Journal of ophthalmology*. 2017;2017.

⁹ Vlasov A, Sia RK, Ryan DS, et al. Sutureless cryopreserved amniotic membrane graft and wound healing after photorefractive keratectomy. *Journal of Cataract & Refractive Surgery*. 2016;42(3):435-443.

¹⁰ Cox AR, Sia RK, Purt B, et al. Assessment of corneal haze after PRK and the effect of sutureless amniotic membrane graft by corneal densitometry. *Journal of Refractive Surgery*. 2020;36(5):293-299.

¹¹ Al-Kharashi S, Al-Khawaja A, Gonnah E-S, et al. Microbial keratitis after amniotic membrane transplantation. *International ophthalmology*. 2005;26(3):73-76.

¹² Turkoglu E, Celik E, Alagoz G. A comparison of the efficacy of autologous serum eye drops with amniotic membrane transplantation in neurotrophic keratitis. *Paper presented at: Seminars in ophthalmology* 2014.

Sample Prior Authorization Request Letter

Diagnosis: Corneal Ulcer

Please include physician letterhead on Prior Authorization Letters

[Date]

[Payor Contact]

[Title]

[Address]

[City, State, Zip]

Re: [Patient Name]

[Patient Identification Number]

[Date of Service]

Dear [Payor Contact]:

I am writing on behalf of my patient, [Insert patient name], to request [Payor name] cover the use of Prokera® to treat their Corneal Ulcer. As you know, a corneal ulcer is an ocular emergency, as corneal ulcers have one thing in common: the potential to cause devastating loss of vision—often rapidly. Treatment for corneal ulcers depends on the cause, and we know that treatment should be started as soon as possible to prevent scarring of the cornea. For this reason, I determined this patient requires placement of Prokera, Cryopreserved Amniotic Membrane[s] (CAMs), to treat their damaged corneas.

Patient History

This patient has [a history of injury, dry eye, incomplete blinking, etc.—ADD PATIENT-SPECIFIC HISTORY that led to corneal ulcer]. If allowed to progress, my patient's corneal ulcer is in danger of causing additional complications including loss of vision. To prevent it from progressing, I have determined that they required the application of a Prokera Cryopreserved Amniotic Membrane (CAM). This patient has a corneal ulcer that studies show, can get clinically significant benefits from the Prokera application.

[Additional patient history, including rationale as to why this is the preferred treatment option to treat the condition of this patient (i.e., patient is not a surgical candidate). Physician may also want to expand upon his/her experience with prior use of Prokera.]

A corneal ulcer is an open sore in the outer layer of the cornea. It is often caused by infection, but severe dry eye or other eye disorders can cause it. In this condition the surface skin of the cornea (the clear window of the eye) breaks down, causing sharp pain, watering, and sometimes blurred vision. Ulcers may be due to injury (corneal abrasion) or other disorders, and in the case of this patient, they developed the corneal ulcer over [xxx days/weeks/months, etc.]. It was my professional opinion that in order to prevent permanent damage to their vision or possible blindness, this patient required the immediate application of Prokera to treat their corneal ulcer.

Published Clinical Evidence

In a retrospective series by D Brocks, published in the 2018 ASCRS/ASOA Symposium and Congress paper, 19 eyes of 19 consecutive patients that presented with corneal ulcers with or without Neurotrophic Keratitis (NK) were treated with Prokera. Five patients required more than one application and two patients required tarsorrhaphy. Concomitant medications included artificial tears, antibiotics, antiviral, steroids, and NSAIDs. All patients had reduced discomfort and

the corneal staining score was reduced from 3.7 ± 0.9 at baseline to 1.8 ± 1.8 at 1-week, 0.9 ± 1.3 at 1-month, and 0.4 ± 0.7 at 6-months.¹

In a Retrospective review by D Brocks, published in *Clinical Ophthalmology* in 2020, of 13 eyes of 13 Pts with recalcitrant corneal ulcers, 9 (69%) of which progressed from Neurotrophic Keratitis (NK). Patients had failed conventional treatments including artificial tears (n = 11), antibiotics (n = 11), ointment (n = 11), steroids (n = 6), and antivirals (n = 3). Follow-ups of ≥ 6 mo. 13/13 ulcers healed in a median of 14-days (range 4-43). Significant improvements in discomfort, corneal staining, and corneal signs at 1-week, 1-month, 3-months, and 6-months. ($p < 0.05$). One case of recurrence. No AE.²

A Retrospective, case-control study of 24 eyes with central and paracentral corneal infectious ulcers, published in *Scientific Reports*, Oct 2020 reported that all patients received SOC including corneal scraping and microbial culture before broad-spectrum antimicrobial antibiotics. Once culture confirmed, target antimicrobial therapy was given. 11 patients received Prokera in addition to SOC. Prokera left for at least 5-days. Placement of PKS had significantly faster epithelialization within 3.56 ± 1.78 weeks vs 5.87 ± 2.20 weeks ($p = 0.01$). Placement of Prokera helped achieve improved epithelialization rates (72.7% vs 23.1% $p = 0.04$). The Prokera group had clinically significant BCSVA (> 3 lines) improvement (81.8% vs 38.4%, $p = 0.047$) compared to SOC. Additionally, the Prokera group had clinically significant total VA improvement (log MAR 0.7 ± 0.6 vs 1.6 ± 0.9 , $p = 0.016$) compared to SOC. Some complaints of foreign body sensation.³

There are many clinical publications supporting the use of Prokera to treat Corneal Ulcers, Recurrent Corneal Erosion (RCE), Neurotrophic Keratitis (NK), corneal ulcers and melts, Stevens-Johnson syndrome, and Persistent Epithelial Defects (PEDs). In addition to the published evidence included in this letter, an additional list of published evidence regarding the treatment of Corneal Ulcers is enclosed.^{4,5}

Based on the information provided, and on behalf of [patient's name], I am asking that you allow coverage for the Prokera used to treat their corneal ulcer, so your member may receive the same clinical benefits that others have received with the use of Prokera. With this treatment, we expect dramatic improvements in their symptoms that they would not achieve without treatment with Prokera.

Should you require additional information, please do not hesitate to contact my office at the information below.

Sincerely,

[Doctor Name]

[Title/Specialty]

[Email address]

¹ Brocks D, Sheha H, Tighe S. (2018) Use of Amniotic Membrane in Corneal Ulcers with or without Neurotrophic Keratitis. 2018 ASCRS/ASOA Symposium and Congress. Paper.

² Brocks D, Mead OG, Tighe S, Tseng SC. Self-Retained Cryopreserved Amniotic Membrane for the Management of Corneal Ulcers. *Clinical Ophthalmology*. 2020 May 26;14:1437-43.

³ Yin HY, Cheng AM, Tighe S, Kurochkin P, Nord J, Dhanireddy S, Swan R, Alpert S. Self-retained cryopreserved amniotic membrane for treating severe corneal ulcers: a comparative, retrospective control study. *Scientific Reports*. 2020 Oct 12;10(1):1-5.

⁴ Sohal RJ, Aung TT, Sohal S, Harish A. A Rare Cause of Bilateral Corneal Ulcers: Vitamin A Deficiency in the Setting of Chronic Alcoholism. *Cureus*. 2020 May;12(5).

⁵ Barrett RT, Hastings JP, Ronquillo YC, Hoopes PC, Moshirfar M. Coral Keratitis: Case Report and Review of Mechanisms of Action, Clinical Management and Prognosis of Ocular Exposure to Palytoxin. *Clinical Ophthalmology* (Auckland, NZ). 2021;15:141.

Sample Prior Authorization Request Letter

Diagnosis: Epithelial Basement Membrane Dystrophy (EBMD)

Please include physician letterhead on Appeal Letters

[Date]

[Payer Contact]

[Title]

[Address]

[City, State, Zip]

Re: [Patient Name]

[Patient Identification Number]

[Date of Service]

Dear [Payer Contact]:

I am writing on behalf of my patient, [Insert patient name], to request [Payer name] cover the use of Prokera® to treat their Epithelial Basement Membrane Dystrophy (EBMD). As you know, EBMD is a disease that affects the anterior cornea, causing characteristic slit lamp findings which may result in decreased vision and/or recurrent corneal erosions. Many patients are asymptomatic although symptoms may include blurry vision, variable vision, foreign body sensation, and pain associated with recurrent corneal erosions. As the scarring from Recurrent Corneal Erosions (RCEs) can result in loss of Best Corrected Visual Acuity (BCVA), I determined this patient requires placement of Prokera, corneal bandage[s], to treat their damaged cornea[s].

Patient History

This patient has [a history of erosions with scarring, etc.—ADD PATIENT-SPECIFIC HISTORY that led to diagnosis]. If allowed to progress, my patient is in danger of additional complications up to and including loss of vision. To prevent it from progressing, I have determined that they require the application of a Prokera Cryopreserved Amniotic Membrane (CAM). Studies show that this patient can get clinically significant benefits from the Prokera application to treat their EBMD.

[Additional patient history, including rationale as to why this is the preferred treatment option to treat the condition of this patient (i.e., patient is not a surgical candidate). Physician may also want to expand upon his/her experience with prior use of Prokera.]

EBMD can have an especially variable prognosis. The disease tends to progress with age although many patients can experience a waxing and waning of symptoms throughout their lives and may result in substantial epithelial erosions developing. To prevent further progress of their disease and treat their [EBMD triggered recurrent corneal erosions] and to help prevent new erosions from occurring, I placed Prokera on this patient's eye(s). A 2022 study by Yeu et al. revealed that the placement of Amniotic Membranes after corneal debridement for EBMD resulted in quicker re-epithelialization.¹

Published Clinical Evidence

Retrospective series over 6-months of seven eyes of five consecutive patients with confirmed EBMD via the screwdriver test were treated with Prokera following epithelial debridement. The endpoint was Epithelialization and Best Corrected Visual Acuity (BCVA).

¹ Yeu E, Hashem O, Sheha H, "Treatment of Epithelial Basement Membrane Dystrophy to Optimize the Ocular Surface Prior to Cataract Surgery," Clin Ophthal, 2022; 16: 785-795.

Results: Complete epithelialization of the defects created by debridement was noted in all seven eyes when Prokera was removed at 3 to 7-days after placement.²

In a Retrospective review by J. Sheppard, et al., published in an article for the 13th International Symposium on Sjögren's Syndrome in 2015, of 40 patients with DED accompanied by Epithelial Basement Membrane Dystrophy (EBMD) in 14 patients (35%) received Prokera. Symptoms (SPEED test and history), signs (slit lamp exam, staining, TBUT) and corneal topography (OPD-III) were assessed.

Results: 38 patients (95%) showed improved fluorescein staining and 34 patients (76%) showed improved symptoms. Of 32 patients with topography data, 30 (94%) showed decreases in higher order aberrations including corneal coma. 16 patients (40%) noted some discomfort initially after insertion, and two (5%) complained of discomfort until the Prokera was removed. There were no significant device-related adverse events.³

There are many clinical publications supporting the use of Prokera to treat a wide range of corneal diseases, including EBMD, Recurrent Corneal Erosion (RCE), Neurotrophic Keratitis (NK), Corneal Ulcers and melts, Stevens-Johnson syndrome, and Persistent Epithelial Defects (PED). In addition to the published evidence included in this letter, an additional list of published evidence regarding the treatment of EBMD is enclosed.

Based on the information provided, and on behalf of your member, [patient's name], I am asking that you allow coverage for the Prokera to be used to treat their EBMD, so they may receive the same clinical benefits that others have received with the use of Prokera. With this treatment, we expect dramatic improvements in their symptoms that they would not achieve without treatment with Prokera.

Should you require additional information, please do not hesitate to contact my office at the information below.

Sincerely,

[Doctor Name]

[Title/Specialty]

[Email address]

² Sheha H, Tighe S. Self-Retained Amniotic Membrane for Epithelial Basement Membrane Dystrophy. 2018 ASCRS/ASOA Symposium and Congress. Poster. 2018.

³ Sheppard J, Yeu E and Tseng S. Sutureless Cryopreserved Amniotic Membrane Transplantation Accelerates Ocular Surface Healing and Topographic Stabilization for Dry Eye Patients. 2015, p.355-6.

Sample Prior Authorization Request Letter

Diagnosis: Hereditary Corneal Dystrophies

Please include physician letterhead on Prior Authorization Letters

[Date]

[Payor Contact]

[Title]

[Address]

[City, State, Zip]

Re: [Patient Name]

[Patient Identification Number]

[Date of Service]

Dear [Payor Contact]:

I am writing on behalf of my patient, [Insert patient name], to request [Payor name] cover the use of Prokera® to treat their Hereditary corneal dystrophy. As you know, corneal dystrophy, a degenerative eye disease, manifests itself in a number of forms. An epithelial corneal dystrophy is characterized by abnormalities of the corneal epithelium and poor adhesion of its basement membrane. Symptomatic patients often experience photophobia, decreased vision, and painful chronic recurrent corneal erosion. Mechanical debridement, superficial keratectomy and phototherapeutic keratectomy are commonly used; however, these procedures may carry a significant risk of postoperative pain, delayed epithelial healing, haze and recurrence.^{4,5} The disadvantages of conventional therapy may be eliminated with the use of Amniotic Membrane following debridement.⁶

These dystrophies are eye diseases that involve changes in the cornea and are usually genetic. Most corneal dystrophies are progressive. In some patients, corneal dystrophy can lead to [corneal erosion, scarring, changes in vision, pain, significant vision impairment, and may require corneal transplant to save the patient's vision.] As my patient's disease was progressing, I determined they require placement of Prokera Cryopreserved Amniotic Membrane (CAM) corneal bandage[s], as they are designed to effectively treat damaged corneas.

Patient History

This patient has [a family history of corneal dystrophy, dry eye, incomplete blinking, etc.—ADD PATIENT-SPECIFIC HISTORY that led to diagnosis of corneal dystrophy. For the past XXXX months/years/etc., they have been treated with X, Y, & Z, with no improvement]. If allowed to progress, my patient would have been in danger of complications including loss of vision. To prevent disease progression, I determined that they require the application of the Prokera CAM. I feel that they would get clinically significant benefits from the application of Prokera and therefore would like to proceed with the insertion.

⁴ Itty S, Hamilton SS, Baratz KH, et al. Outcomes of epithelial debridement for anterior basement membrane dystrophy. *Am J Ophthalmol*. 2007; 144(2):288–289.

⁵ Sridhar MS, Rapuano CJ, Cosar CB, et al. PTK versus diamond burr polishing of Bowman's membrane in the treatment of recurrent corneal erosions associated with anterior basement membrane dystrophy. *Ophthalmology*. 2002; 109(4):674–679.

⁶ Huang Y, Sheha H, Tseng SCG. Self-retained Amniotic Membrane for Recurrent Corneal Erosion. *J Clin Exp Ophthalmol* 2013, 4:272-276.

[Additional patient history, including rationale as to why this is the preferred treatment option to treat the condition of this patient (i.e., patient is not a surgical candidate). Physician may also want to expand upon his/her experience with prior use of Prokera.]

Corneal dystrophies are a group of rare, genetic diseases that affect the cornea, the front part of the eye. There are more than 20 types, each with different symptoms. All cause a buildup of foreign material in one or more layers of the cornea. Over time, vision may become cloudy or blurry. It was my professional opinion that in order to prevent permanent damage to their vision or possible blindness, this patient required the immediate application of Prokera to treat their cornea.

Published Clinical Evidence

There are many clinical publications supporting the use of Prokera to treat a wide variety of corneal diseases including: hereditary corneal dystrophy, corneal ulcers, RCEs, NK, corneal melts, Stevens-Johnson syndrome, and PEDs. In addition to the published evidence included in this letter, an additional list of published evidence regarding the treatment of Corneal Dystrophies is enclosed.^{7,8,9,10,11}

Based on the information provided, and on behalf of my patient, I am asking that you allow coverage for the Prokera I used to treat their corneal dystrophy, so your member will have the clinical benefits that others have received from Prokera without the substantial financial burden. With this treatment, we expect dramatic improvements in their symptoms that they would not achieve without Prokera treatment.

Should you require additional information, please do not hesitate to contact my office at the information below.

Sincerely,

[Doctor Name]

[Title/Specialty]

[Email address]

⁷ Sheha H, Tighe S. Self-Retained Amniotic Membrane for Epithelial Basement Membrane Dystrophy. 2018 ASCRS/ASOA Symposium and Congress. Poster. 2018.

⁸ Sheha H. Self-Retained Amniotic Membrane after Debridement for Epithelial Basement Membrane Dystrophy. *Insights in Ophthalmology*. 2018;4.

⁹ Yeu E, Hashem O, Sheha H. Treatment of Epithelial Basement Membrane Dystrophy to Optimize the Ocular Surface Prior to Cataract Surgery. *Clinical Ophthalmology* (Auckland, NZ). 2022;16:785.

¹⁰ Hauswirth. The Effect of Debridement and Amnion Tissue on Vision in Patients with Anterior Basement Membrane Dystrophy: A Short Case Series. *Invest. Ophthalmol. Vis. Sci.* 2015; 56(7):5641.

¹¹ Sheppard J, Yeu E and Tseng S. Sutureless Cryopreserved Amniotic Membrane Transplantation Accelerates Ocular Surface Healing and Topographic Stabilization for Dry Eye Patients. 13th International Symposium on Sjögren's Syndrome. 2015; 355-6

Sample Appeal Letter – Prokera

Denial Reason: Experimental & Investigational

Please include physician letterhead on Prior Authorization Letters

[Date]

[Payor Contact]

[Title]

[Address]

[City, State, Zip]

Re: [Patient Name]

[Patient Identification Number]

[Date of Service]

Dear [Payor Contact]:

I am disputing the denial of CPT 65778 for my patient, which was denied for [input reason for denial] which was used to treat their [insert diagnosis]. [Name of Payor] currently considers the use of Cryopreserved Amniotic Membrane (CAM) without sutures to be experimental and investigational. To date, [include tried therapies] have been tried to resolve [patient's name] condition, but all have failed. My patient's eye condition was deteriorating, and they were at risk of further corneal ulceration or perforation. As such, I believe Prokera was a medically necessary next logical step in their treatment protocol, to provide them relief from the symptoms associated with this disease, heal their cornea, and restore their quality of life.

[Physician should provide some additional rationale as to why this is the preferred treatment option to treat the condition of this patient (i.e., patient is not a surgical candidate). Physician may also want to expand upon their experience with CAM compared to Dehydrated Amniotic Membrane (DAM).]

Prokera is a Cryopreserved Amniotic Membrane fastened to a conformer ring system. The conformer ring sits on the ocular surface like a symblepharon ring, and the stromal side of the CAM is in contact with the corneal surface and limbal area. The CAM provides natural therapeutic biologic actions that include reduction in scarring, blood vessel formation, and inflammation, while promoting the healing of the ocular surface and reducing patient pain. The ring also helps maintain space in the orbital cavity and to prevent conjunctival closure or adhesions. Prokera was cleared by the FDA as a Class II Medical Device in 2003—nearly 20 years ago. It is the only Medical Device cleared by the FDA that can claim anti-inflammatory, anti-scarring, anti-angiogenic properties. Prokera has also been shown to assist in corneal nerve regeneration (See Thomas study reference below) and is indicated and has successfully been treating ocular surface damage and underlying inflamed stroma for many years and is considered standard of care.

The placement of Prokera is reported with the Category I CPT code 65778 (Placement of Amniotic Membrane on the ocular surface; without sutures) which was established in 2011 by the AMA. The establishment of a Category I code indicates that a technology meets the following criteria:

- All devices and drugs necessary for performance of the procedure of service have received FDA clearance or approval when such is required for performance of the procedure or service.
- The procedure or service is performed by many physicians or other qualified health care professionals across the US;
- The procedure or service is performed with frequency consistent with the intended clinical use (i.e., a service for a common condition should have high volume, whereas a service commonly performed for a rare condition may have low volume);
- The procedure or service is consistent with current medical practice; and
- The clinical efficacy of the procedure or service is documented in literature that meets the requirements set forth in the CPT code change application.¹

Covering the use of Prokera to treat my patient's [insert diagnosis] has many advantages, including the fact that Prokera does not require sutures to deliver the therapeutic benefits. The advantage of a sutureless approach is that it facilitates easier treatment because it can be performed in the office setting instead of in a surgical facility, thereby providing convenience and cost savings. This sutureless procedure is performed nationwide by both ophthalmologists and optometrists to treat various ocular surface disorders, and is covered by Medicare, and most major commercial carriers, such as **Aetna, Blue Cross Blue Shield, Humana, etc.** It has long been recognized as a standard of care to treat diseases that cause ocular surface damage or inflammation.

There are several clinical publications supporting the use of Prokera to treat Neurotrophic Keratitis (NK), corneal ulcers and melts, Stevens-Johnson syndrome, Persistent Epithelial Defects (PEDs) – the same indications that are considered acceptable and not experimental or investigational in any way, using sutured DAM grafts under this Policy.

2,3,4,5,6,7,8,9,10,11,12,13

The Prokera CAM device was evaluated in 2018 by Cheng et al. This retrospective review assessed a 48-year-old patient with a 10-year history of rheumatoid arthritis under systemic immunomodulation developed non-resolved severe ocular dryness, pain, photophobia, recurrent diffuse Superficial Punctate Keratitis (SPK), and blurred vision due to corneal epithelial keratopathy OD much worse than OS despite topical artificial tears, steroids, cyclosporine, autologous serum drops, punctal plugs and scleral lens for the last 3-years. Over the course of the first year, this patient was treated with punctal cauterization and a total of 6 CAM (Prokera Slim), each for an average of 7.2 ± 2.3 days, for their recurrent diffuse Superficial Punctate Keratitis (SPK) with filaments. During the first year, the average symptom-free period was 2.4 ± 0.9 months and visual acuity improvement from 20/400 to 20/200. During the next 2-years, she received surgical closure of puncta for recurrent punctal reopening, additional systemic immunomodulation and a total

¹ <https://www.ama-assn.org/practice-management/criteria-cpt-category-i-and-category-iii-codes>

² Pachigolla G, Prasher P, Di Pascuale MA, et al. Evaluation of the role of Prokera in the management of ocular surface and orbital disorders. *Eye Contact Lens*. 2009; 35:172-175.

³ Suri K, Kosker M, Raber IM, et al. Sutureless Amniotic Membrane Prokera for Ocular Surface Disorders: Short-Term Results. *Eye Contact Lens*. 2013; 39:341-347.

⁴ Sheha H, Liang L, Li J, et al. Sutureless amniotic membrane transplantation for severe bacterial keratitis. *Cornea*. 2009; 28:1118-1123.

⁵ Sheha H, Tighe S, Cheng AM, et al. Amniotic Membrane Transplantation. In: Ichhpujani P, Spaeth G, Yanoff M (Eds); *Expert Techniques in Ophthalmic Surgery*. JAYPEE Publishers; 2015 (20) 167-175.

⁶ Huang YS, Sheha H, Tseng SC. Self-retained Amniotic Membrane Transplantation for Recurrent Corneal Erosion. *J Clin Exp Ophthalmol*. 2013; 4:272.

⁷ Kheirkhah A, Johnson DA, Paranjpe DR, et al. Temporary sutureless amniotic membrane patch for acute alkaline burns. *Arch Ophthalmol*. 2008; 126:1059-1066

⁸ Shammas MC, Lai EC, Sarkar JS, et al. Management of acute Stevens-Johnson syndrome and toxic epidermal necrolysis utilizing amniotic membrane and topical corticosteroids. *Am J Ophthalmol*. 2010; 149:203-213.

⁹ Shay E, Khadem JJ, Tseng SC. Efficacy and limitation of sutureless amniotic membrane transplantation for acute toxic epidermal necrolysis. *Cornea*. 2010; 29:359-361.

¹⁰ Tomlins PJ, Parulekar MV, Rauz S. "Triple-TEN" in the Treatment of Acute Ocular Complications from Toxic Epidermal Necrolysis. *Cornea*. 2013; 32:365-369.

¹¹ Kolomeyer AM, Do BK, Tu Y, Chu DS. Placement of Prokera in the management of ocular manifestations of acute Stevens-Johnson syndrome in an outpatient. *Eye Contact Lens*. 2013;39: e7-11.

¹² Cheng AMS, Tighe S, Sheha H and Tseng SCG. Adjunctive role of self-retained cryopreserved amniotic membrane in treating immune-related dry eye disease. *International Ophthalmology*. 2018;38: 2219-22[122]

¹³ John T, Tighe S, Sheha H, et al. Corneal Nerve Regeneration after Self-Retained Cryopreserved Amniotic Membrane in Dry Eye Disease. *J Ophthalmology* 2017; Volume 2017, Article ID 6404918, 10 pages. <https://doi.org/10.1155/2017/6404918>

of four CAM (PKS), each for an average of 8.5 ± 2 days, for recurrent scattered SPK. By year-2 and year-3, she achieved an average symptom-free period of 6.4 ± 1 -month and visual acuity improvement from 20/200 to 20/70.

In a clinical study Published in Aug 2017, Thomas John, MD conducted a prospective randomized clinical trial that compared the use of Prokera to conventional maximum treatment. The overall dry eye symptoms including discomfort and visual disturbances were significantly improved in the study group over the course of the study yet remained constant in the control group. The study group demonstrated a significant increase in corneal nerve density ($12,241 \pm 5083 \mu\text{m}/\text{mm}^2$ at baseline, $16,364 \pm 3734 \mu\text{m}/\text{mm}^2$ at 1-month, and $18,827 \pm 5453 \mu\text{m}/\text{mm}^2$ at 3-months, $p = 0.015$). This was accompanied by an increase in corneal sensitivity (3.25 ± 0.6 cm at baseline, 5.2 ± 0.5 cm at 1-month, and 5.6 ± 0.4 cm at 3-months, $p < 0.001$) and corneal topography. The control group, however, remained unchanged.

The references provided above support the safety and efficacy of the use of CAM without sutures for several ocular indications, including [patient diagnosis]. The attached patient records support their medical necessity of this treatment. We ask that you reconsider your claim denial based upon the patient's medical necessity and proven safety and efficacy of CAM without sutures for ocular use and authorize prompt payment of this claim. If you have any questions or require additional information regarding the procedure or patient, please do not hesitate to contact me.

Sincerely,

[Physician Name]

[Email]

[Phone]

Need additional assistance?

Contact The Pinnacle Health Group

BioTissue has enlisted **The Pinnacle Health Group** to assist with Reimbursement Support. Pinnacle provides help via a Hotline or can be accessed via email. Their team of credentialed professional coders can provide support to physicians and facilities and answer many reimbursement questions. They can provide:

- Coding guidance for BioTissue products
- Coverage criteria for specific payors
- Claim appeals and underpayment support
- Benefit verification and prior authorization requests
- Reimbursement and guidance documents
- Coding guide
- Letter of Medical Necessity
- Appeal Templates



Email: biotissueocular@thepinnaclehealthgroup.com

Phone: 866-369-9290

Fax: 877-499-2986

Hours: Monday to Friday: 8:30 AM – 6:00 PM ET